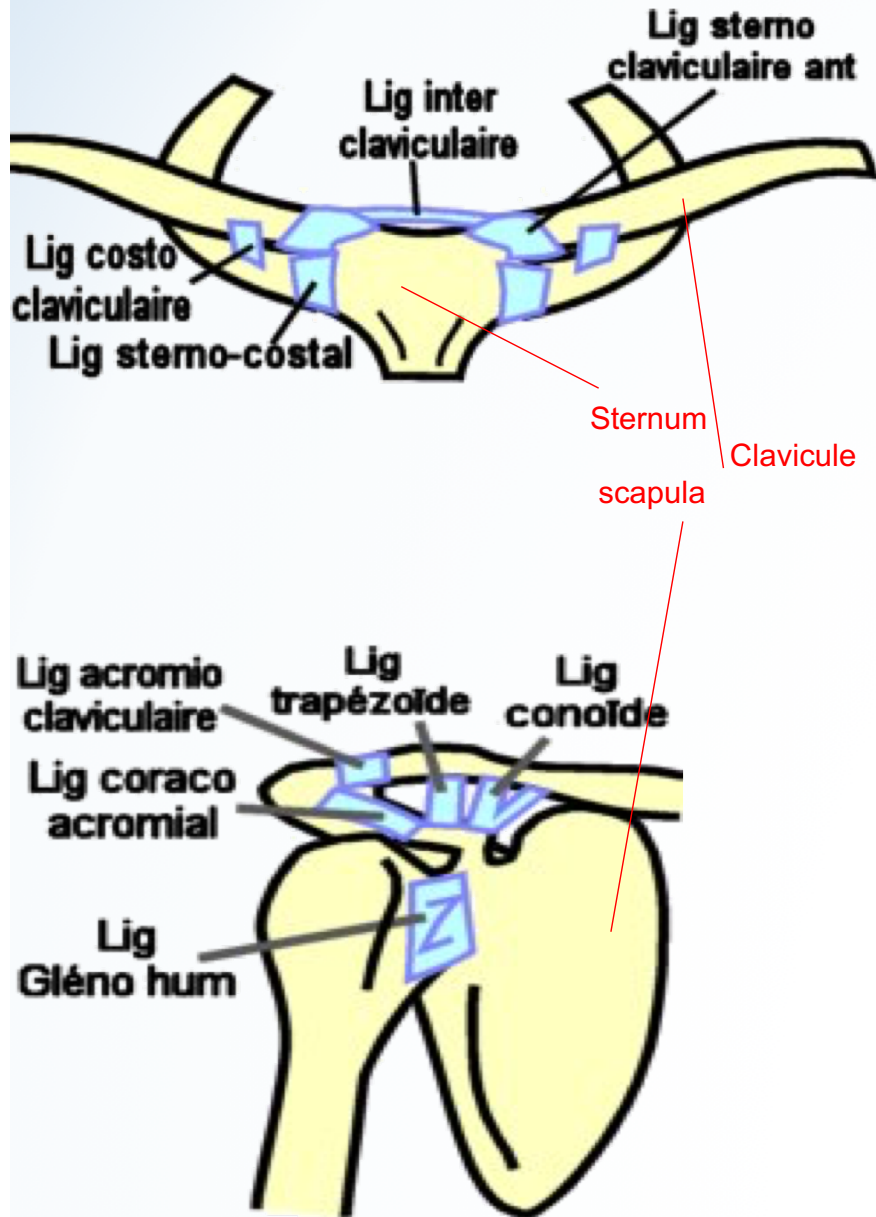


Ceinture Scapulaire

C - Moyens d'Union



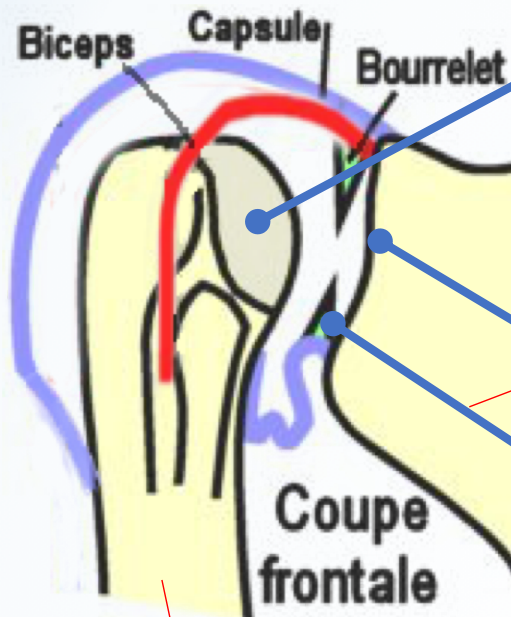
ÉPAULE

B - Surfaces articulaires

Cf. ostéo

Sur l'humérus

- tête humérale



Sur la Scapula

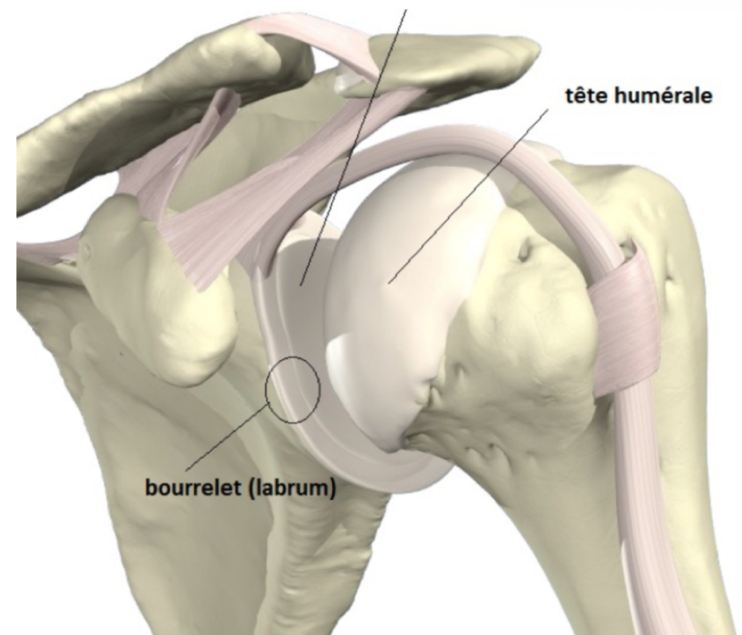
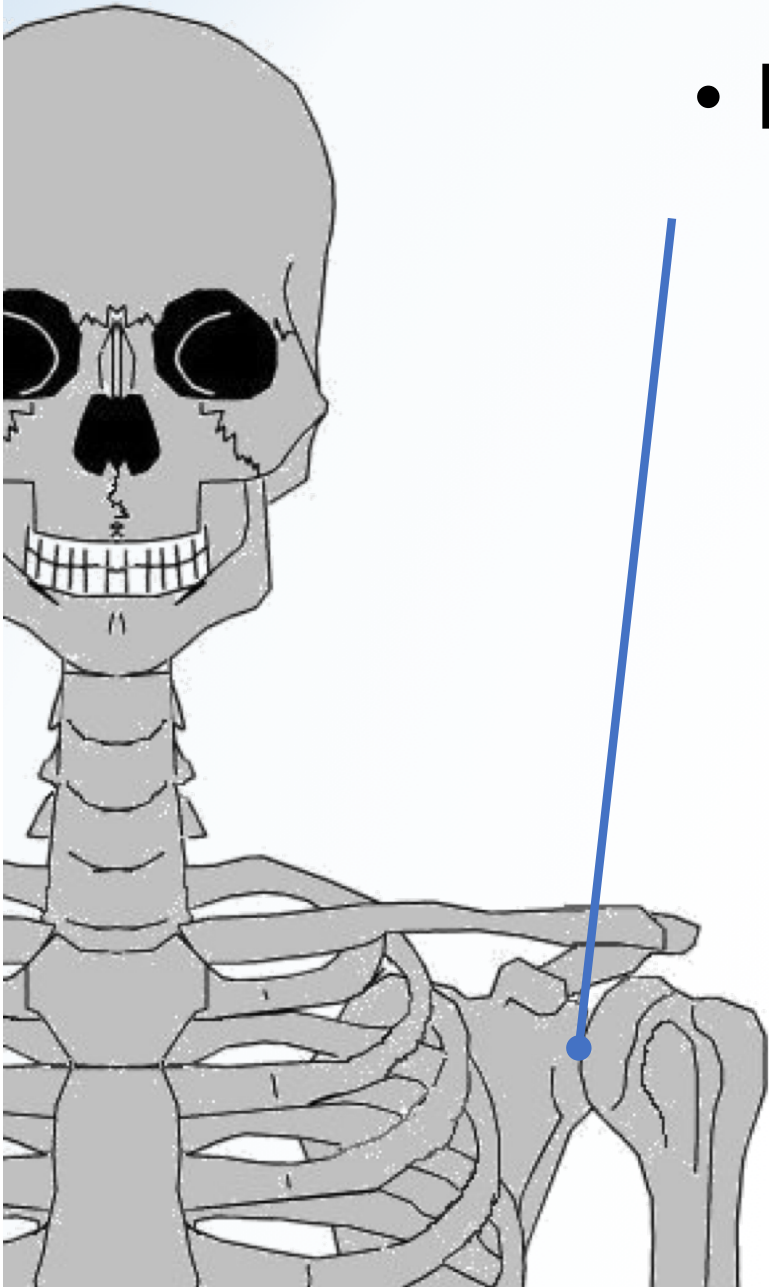
- Cavité glénoïdale
- Bourrelet glénoïdien...

Humérus

Ceinture Scapulaire

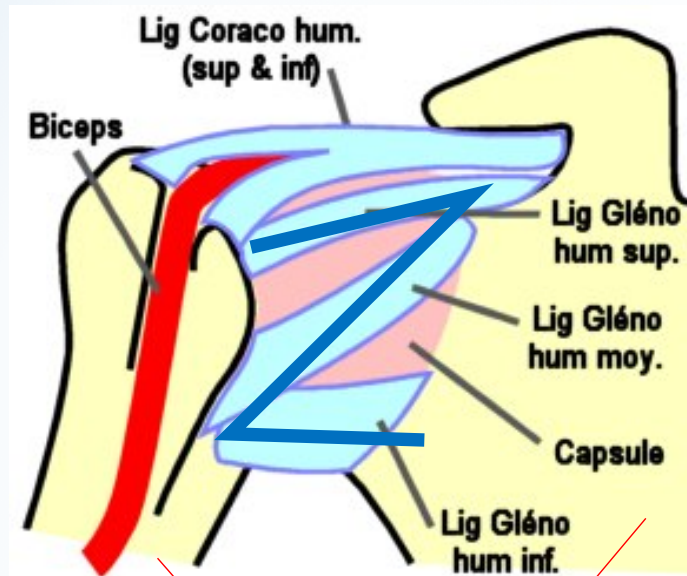
B - Surfaces articulaires (suite)

- Bourrelet glénoïdien =



ÉPAULE

C - Moyens d'Union



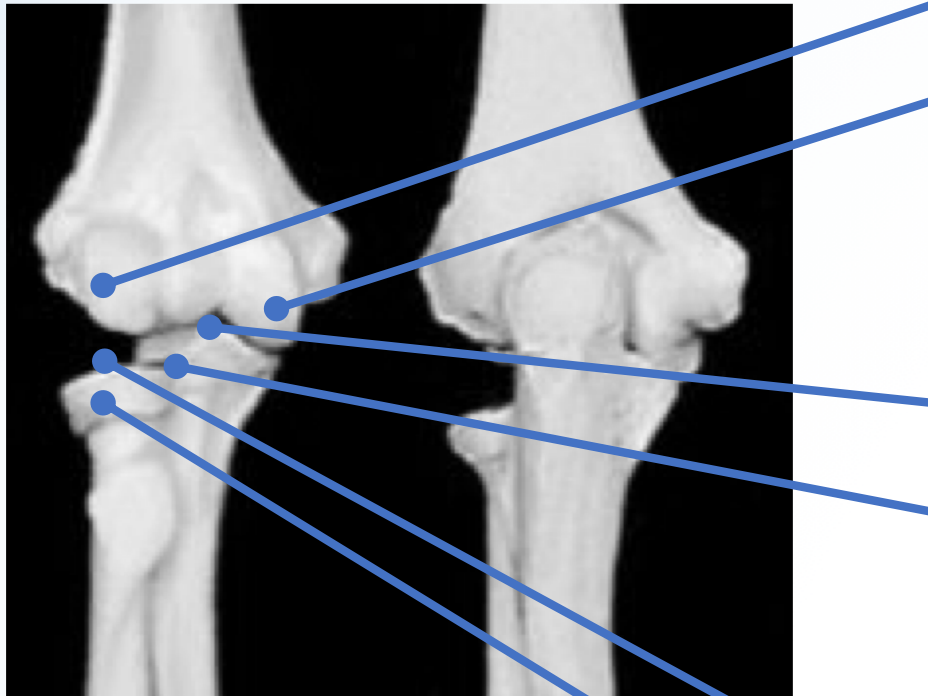
Humérus

Scapula

Complexe du coude

B - surfaces Articulaires

Cf. ostéo



Vue ant

Coude DR

vue post

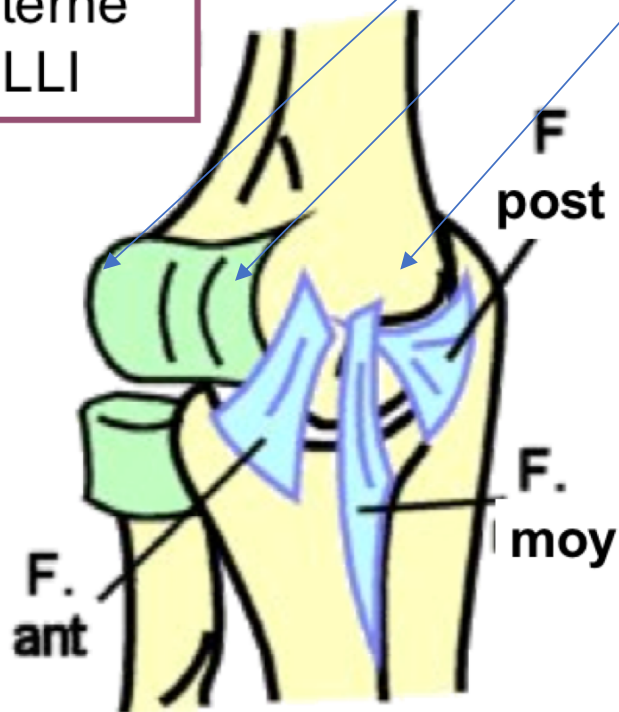
Complexe du coude

C - Moyens d'Union

Capitulum
Trochlée
Epicondyle médial

Vue INT

Lig latéral interne
LLI

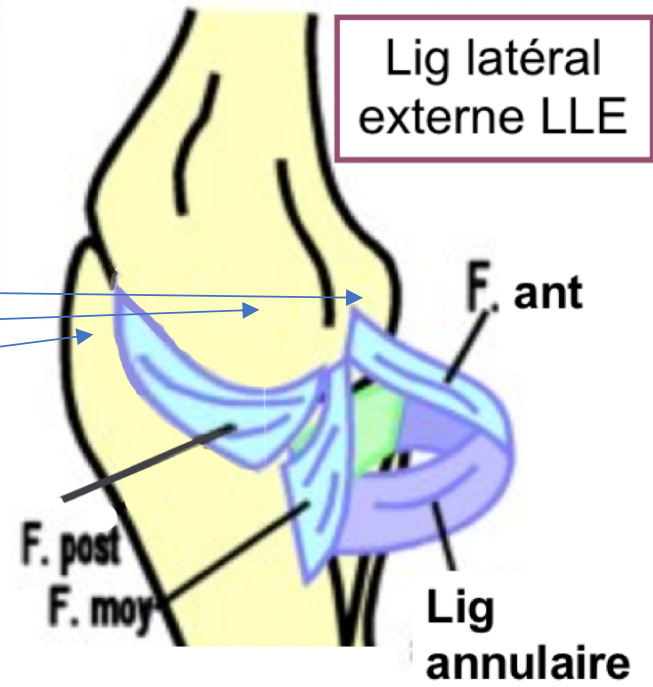


Complexe du coude

C - Moyens d'Union

Capitulum
Epicondyle latéral
Olécrane de Ulna

Vue EXT sans Radius

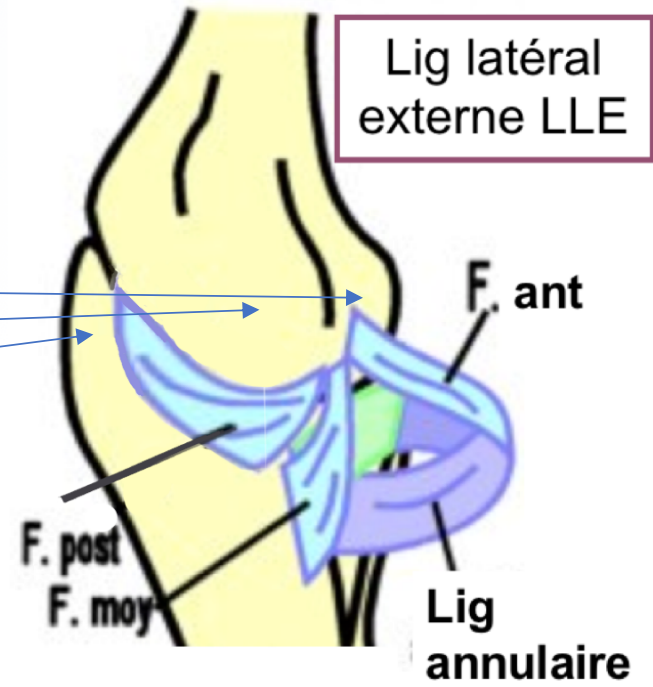


Complexe du coude

C - Moyens d'Union

Capitulum
Epicondyle latéral
Olécrane de Ulna

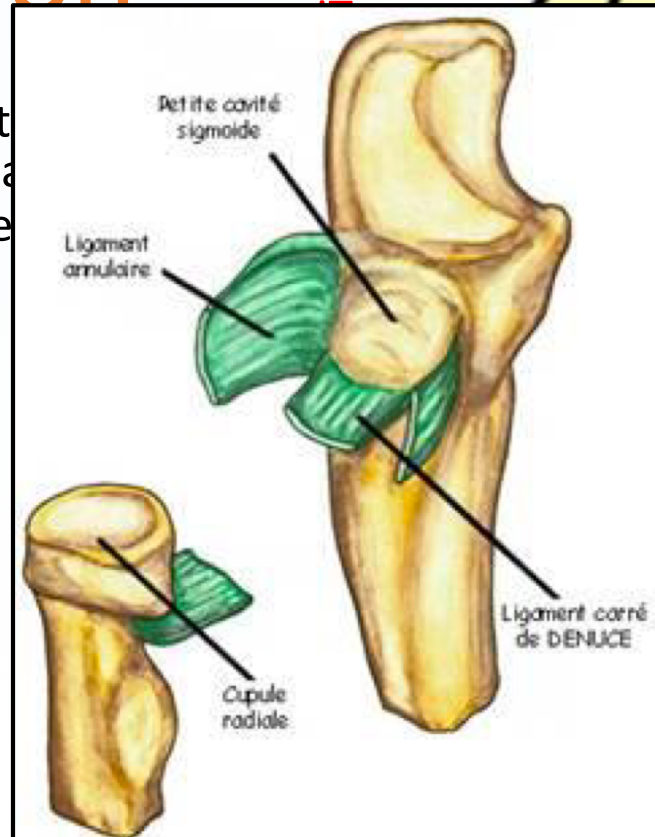
Vue EXT sans Radius



Complexe du coude

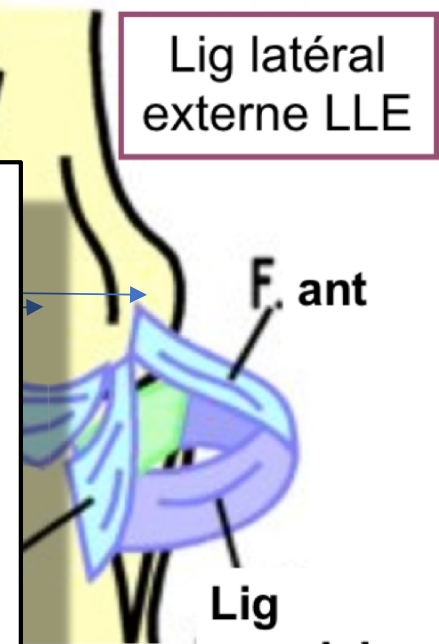
C - Moyens d'Union

Capitulum
Epicondyle latéral
Olécrane de l'ulna



US

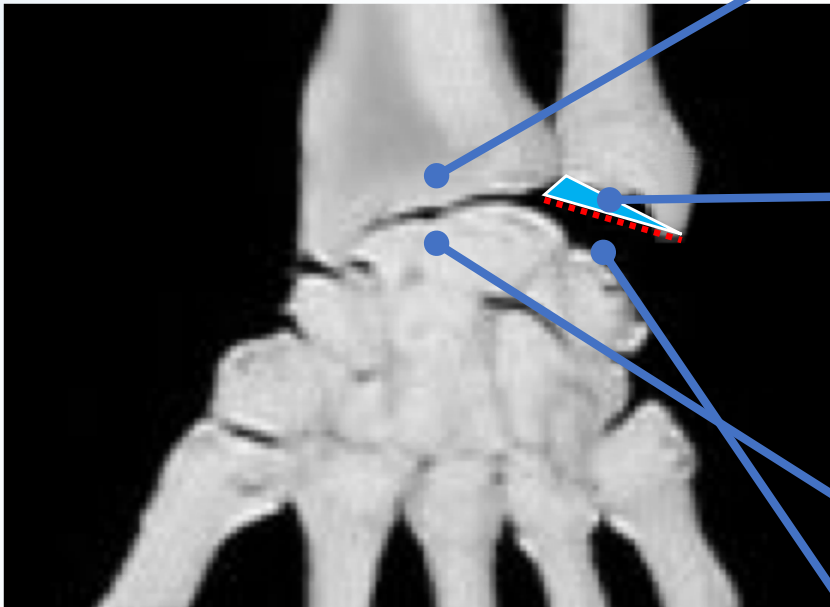
Lig latéral externe LLE



POIGNET

B - Surfaces articulaires

Cf. ostéo



Entre Ulna et Radius

• Lig triangulaire

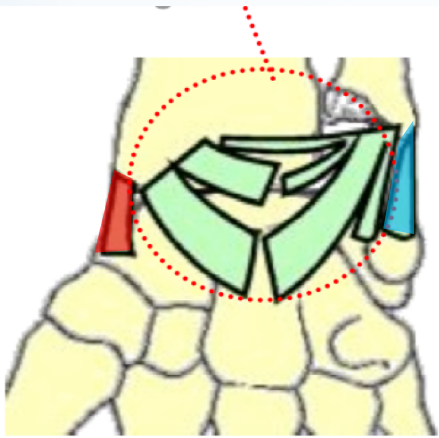
Lig triangulaire

Du radius → Processus styloïde Ulna

POIGNET

C - Moyens d'Union

Vue ANT



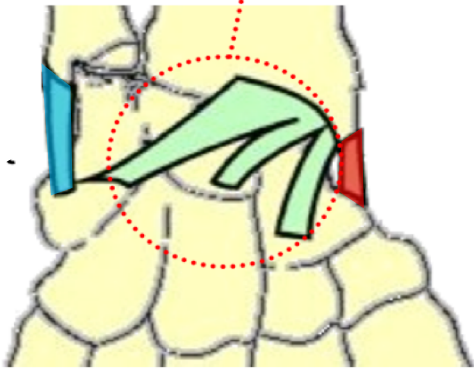
En AV

- Ligament palmaire

POIGNET

C - Moyens d'Union

Vue POST

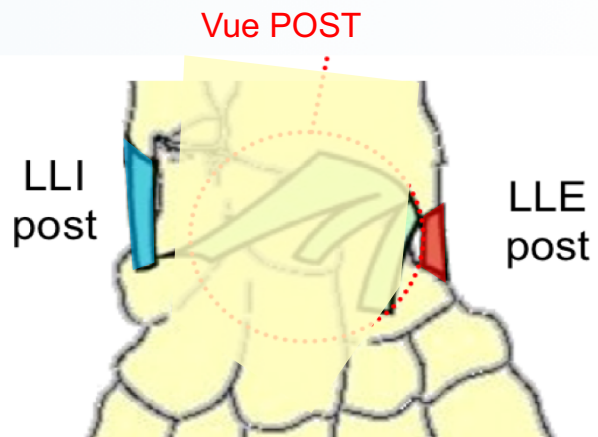
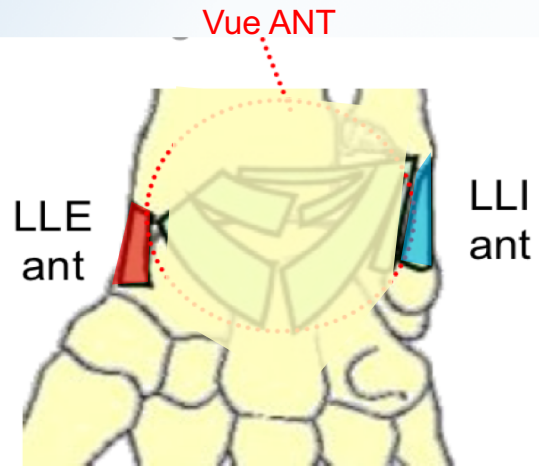


En ARR

- Ligament dorsal

POIGNET

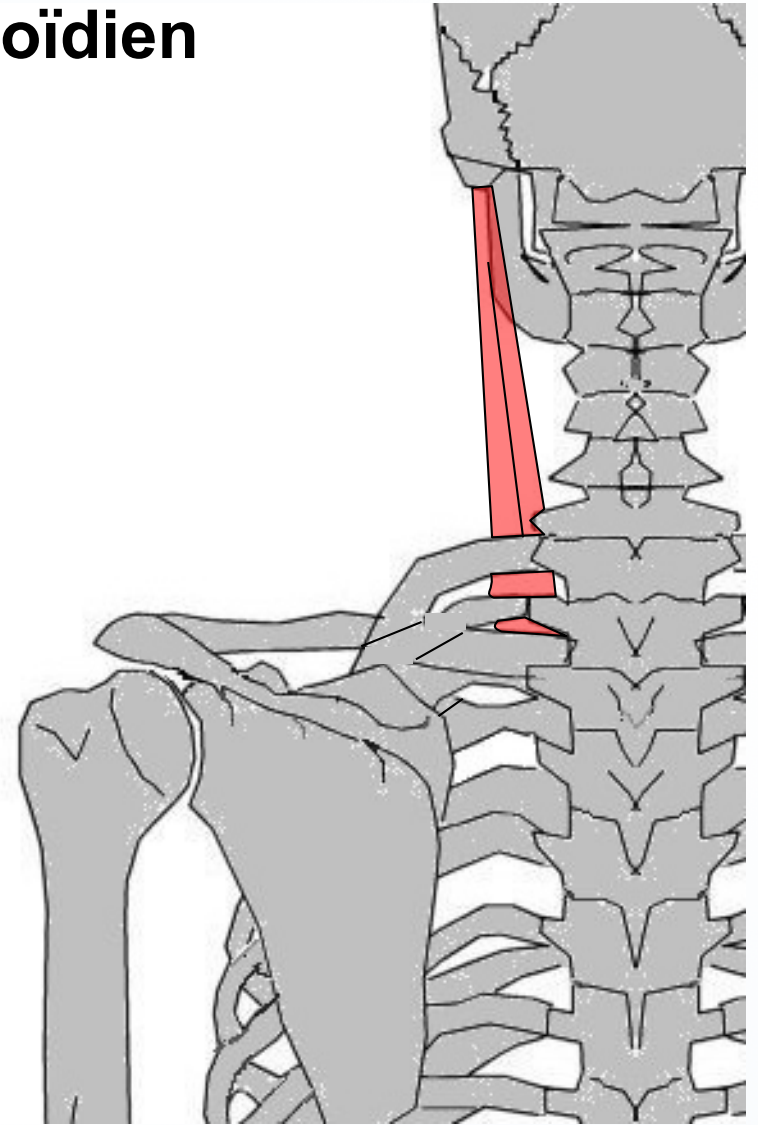
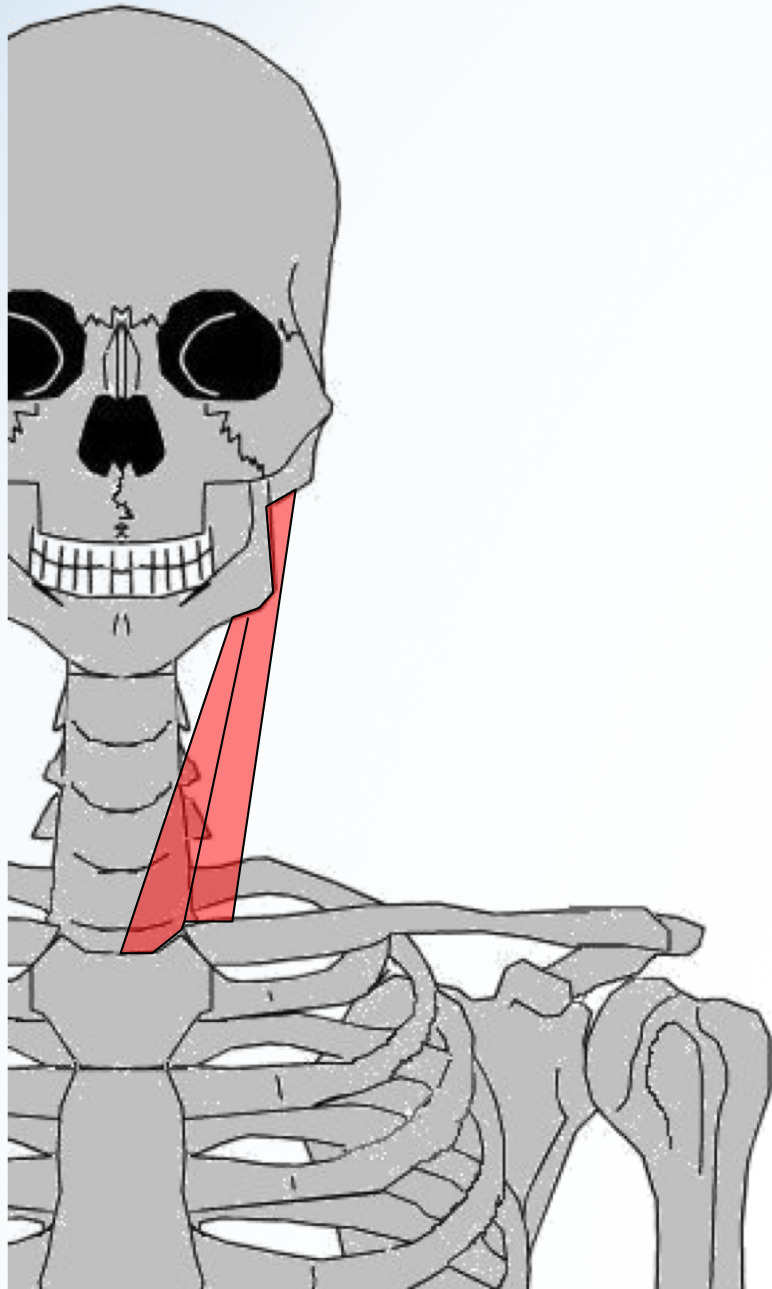
C - Moyens d'Union





MYOLOGIE
membre sup

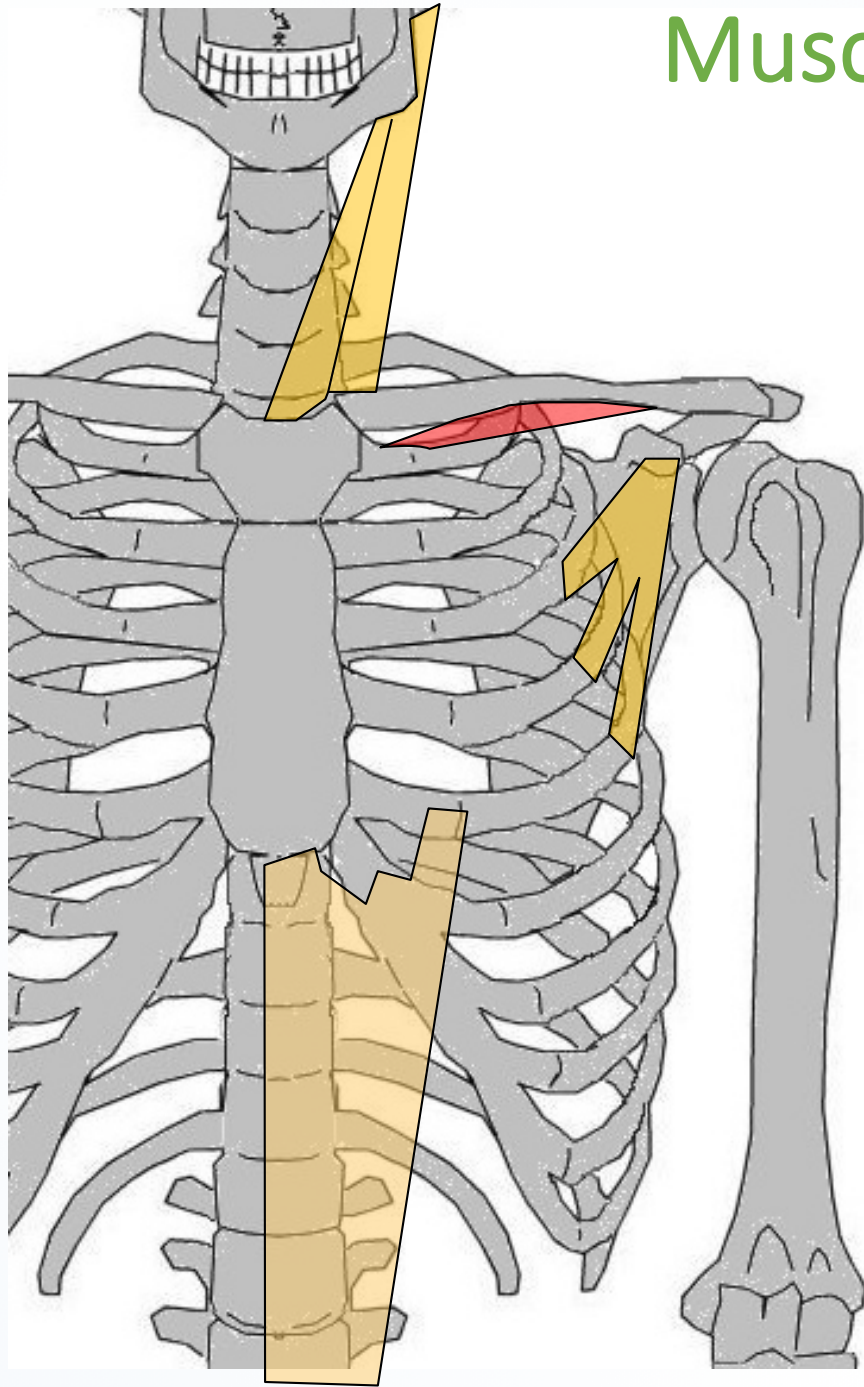
Sterno-cléïdo-mastoïdien



Muscl. de la Ceint. Scapulaire

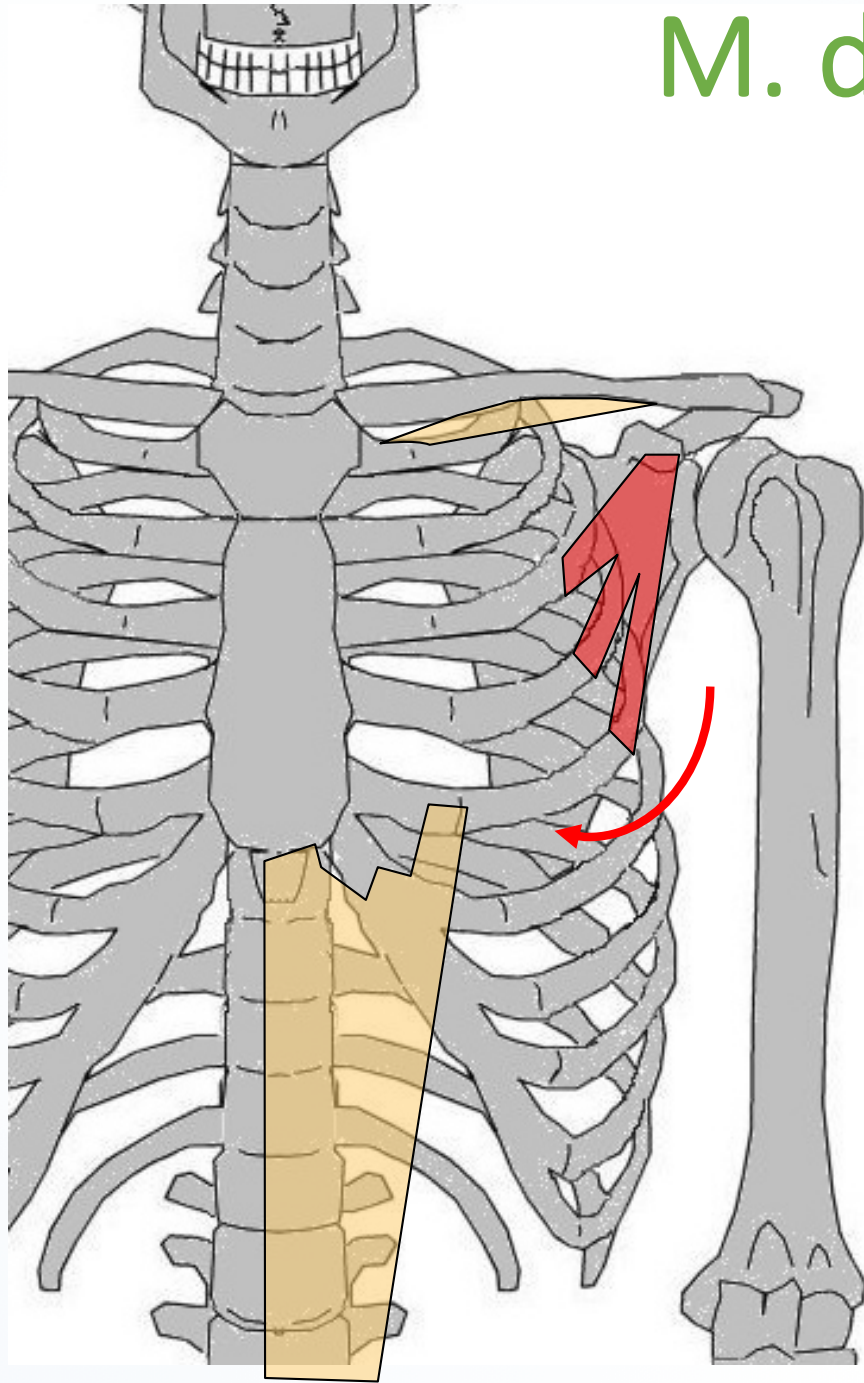
Muscl. de la Ceint. Scapulaire

Sub-clavier

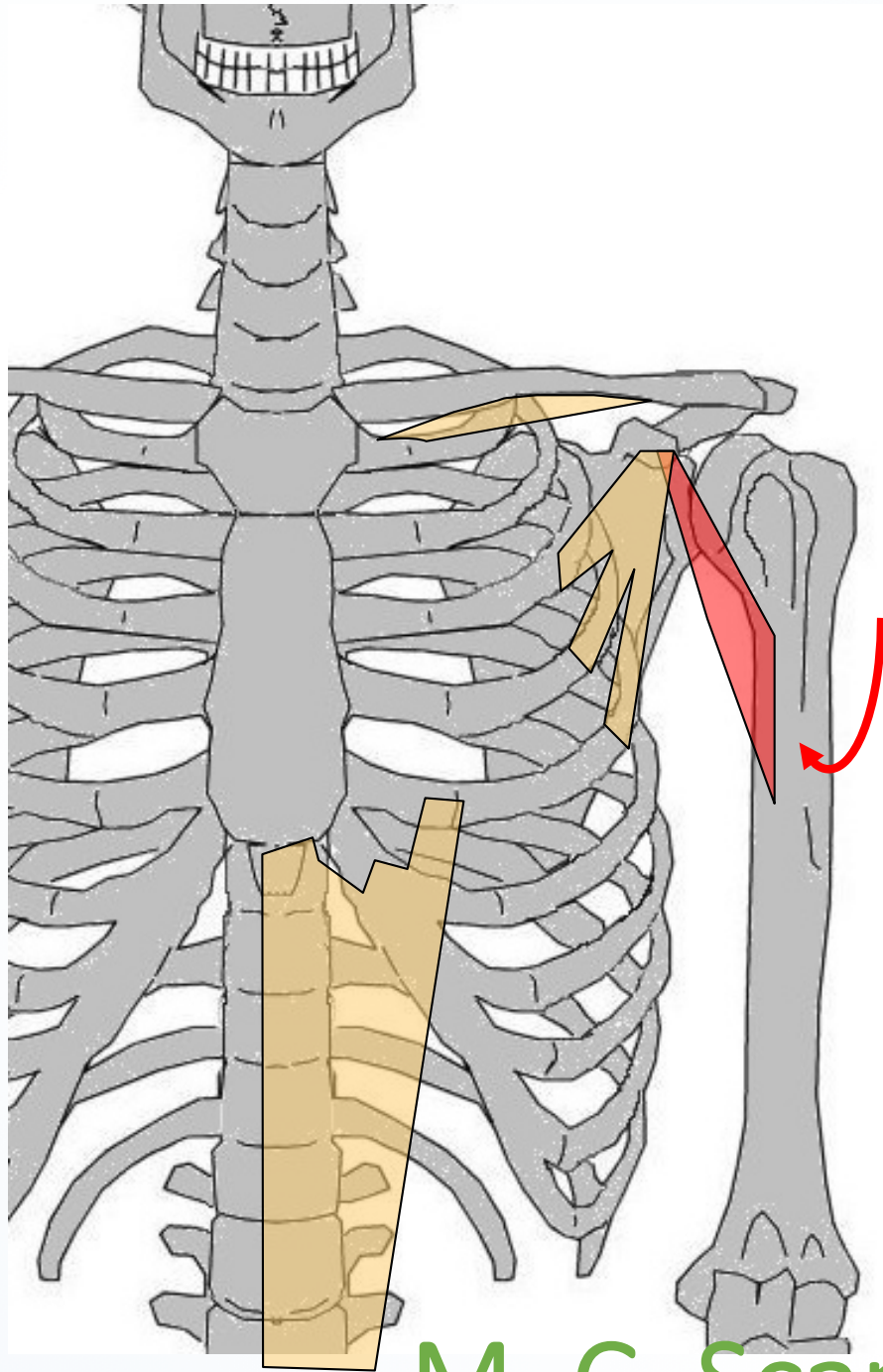


M. de Ceint. Scapulaire

Petit pectoral

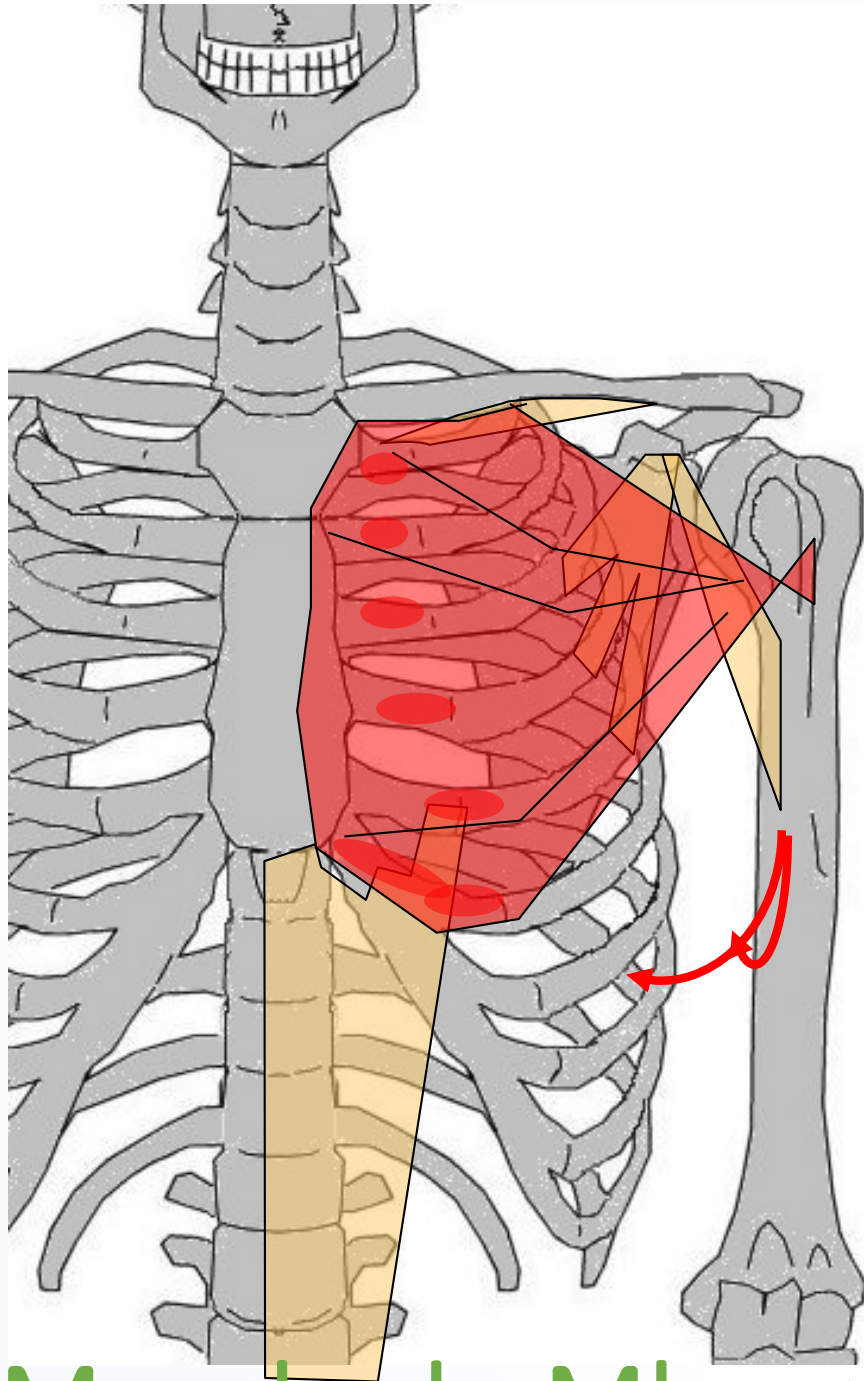


Coraco-brachial



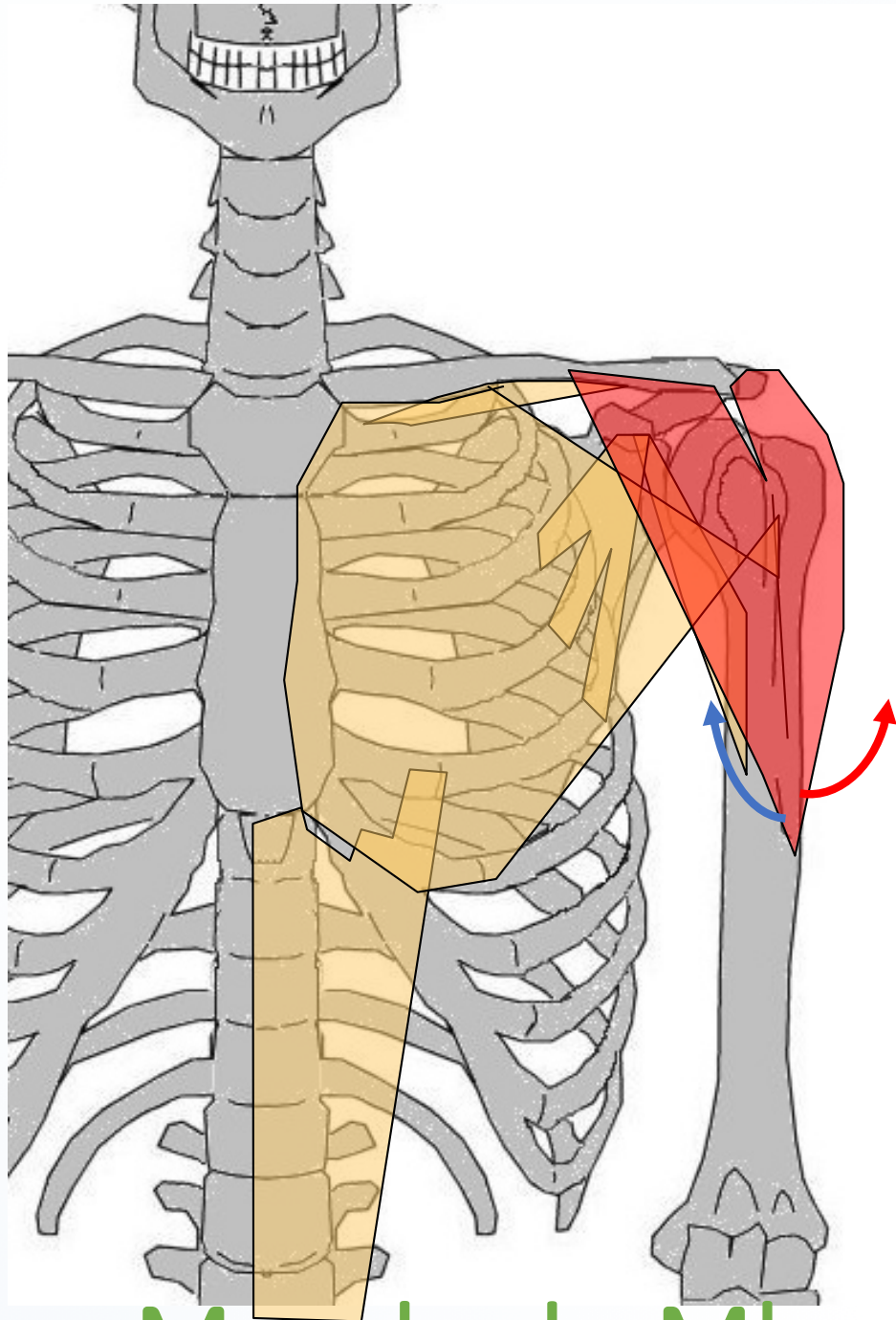
M. C. Scapul^R & Mbre sup

Grand Pectoral

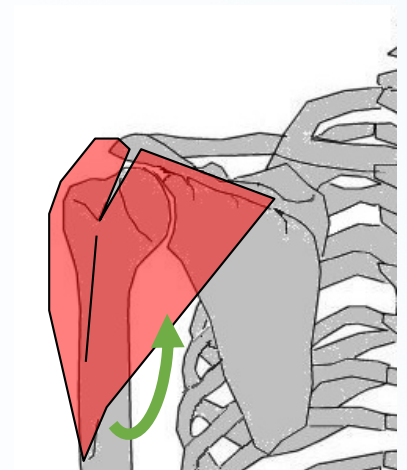


Muscle du Mbre >

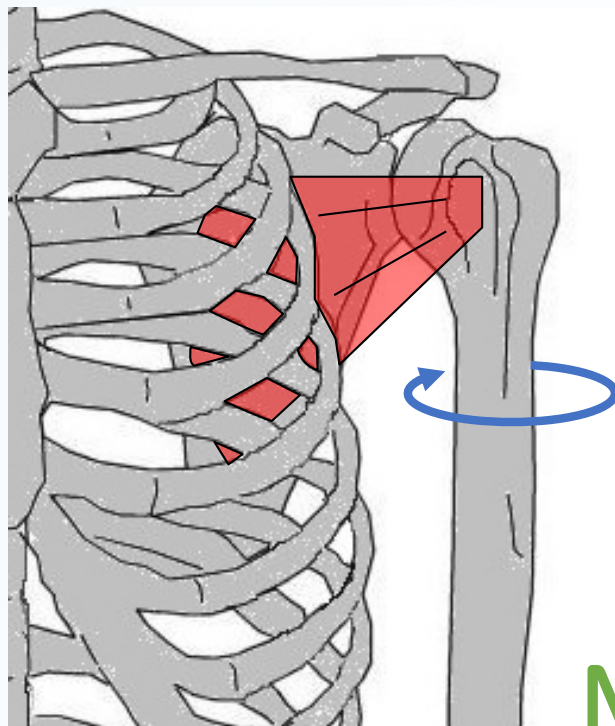
Deltoïde



Muscle du Mbre >



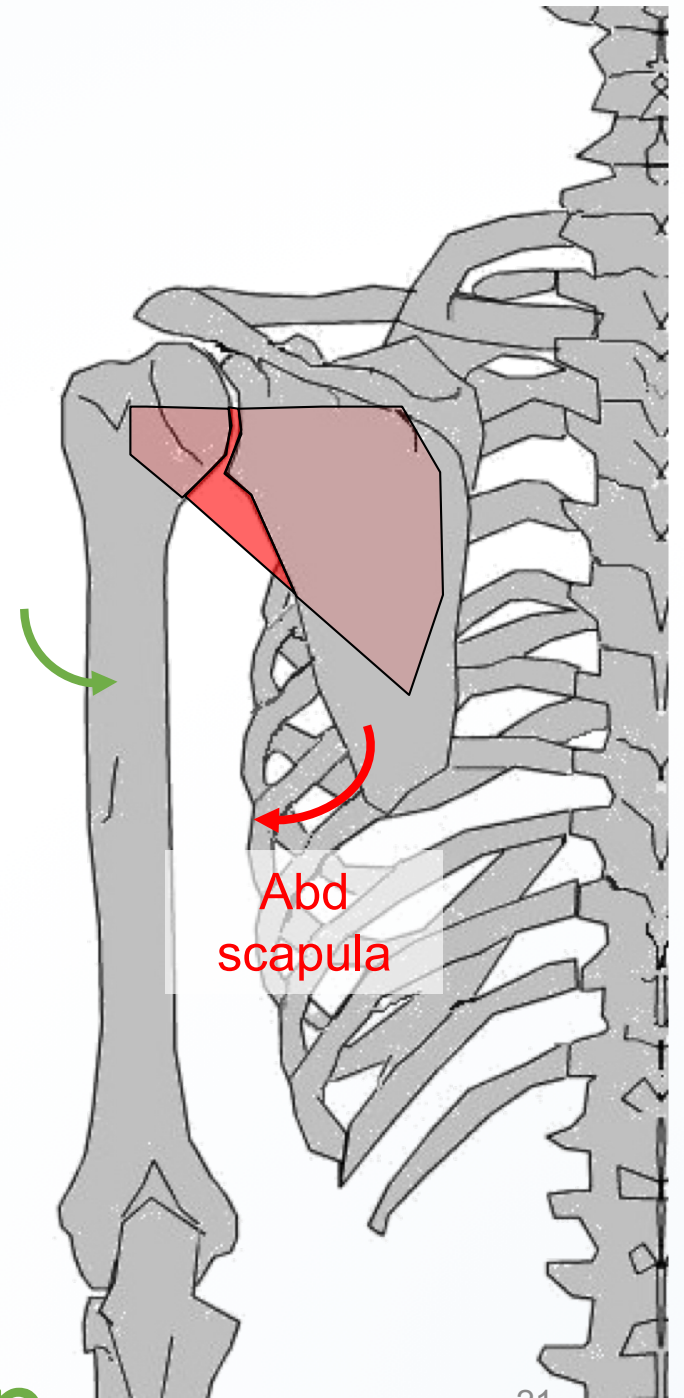
Sub-scapulaire



Rot int.

M du mbre sup

ADD
humérus



Abd
scapula

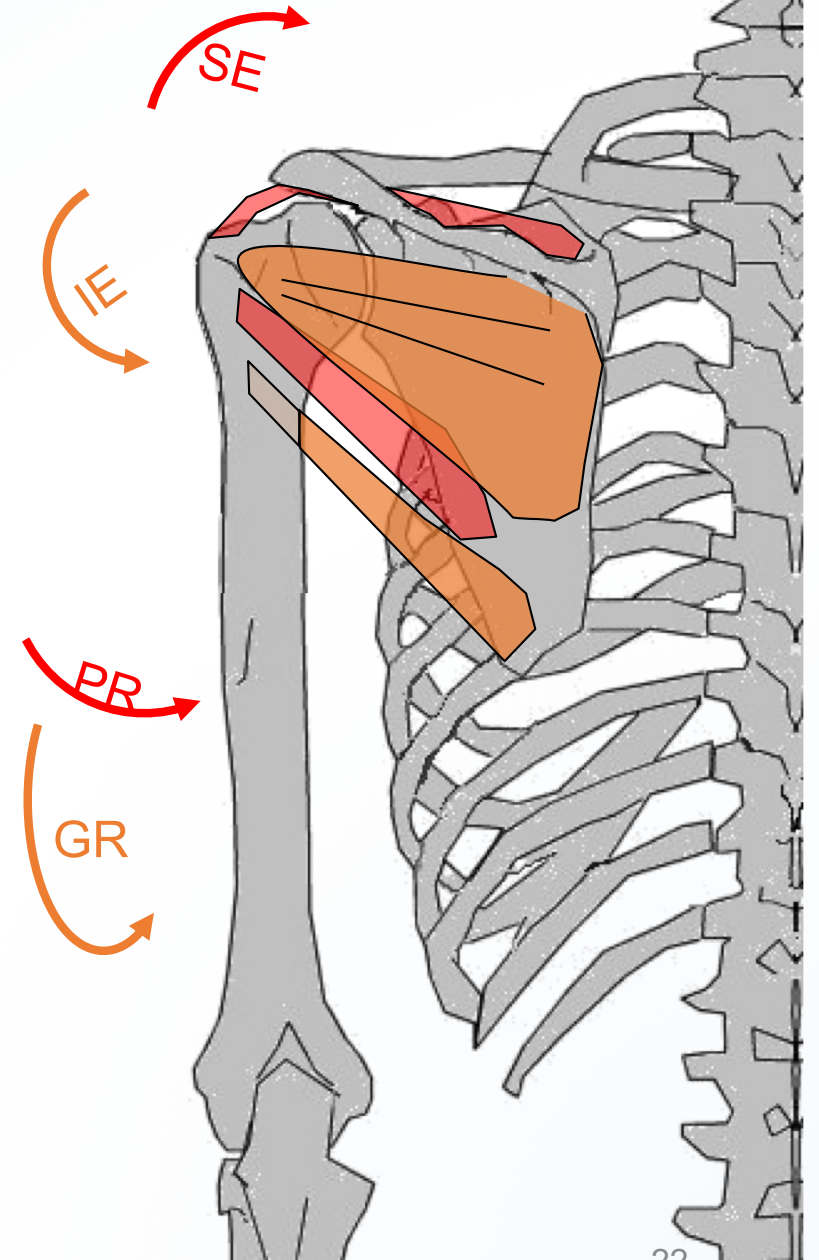
M du Mbre sup

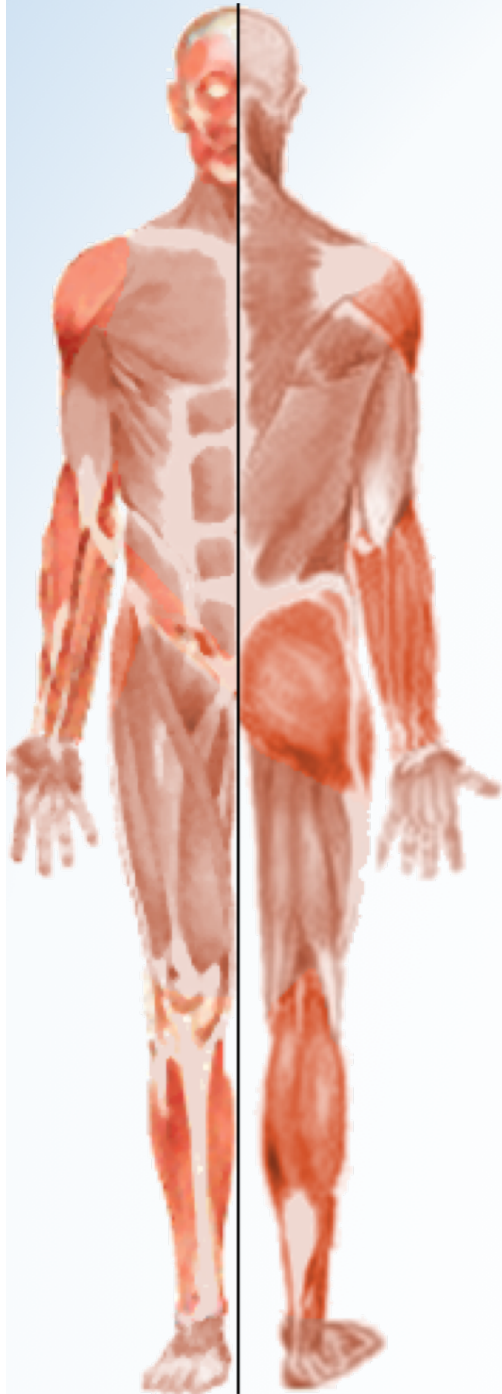Supra-épineux (SE)

Infra-épineux (IE)

Petit rond (PR)

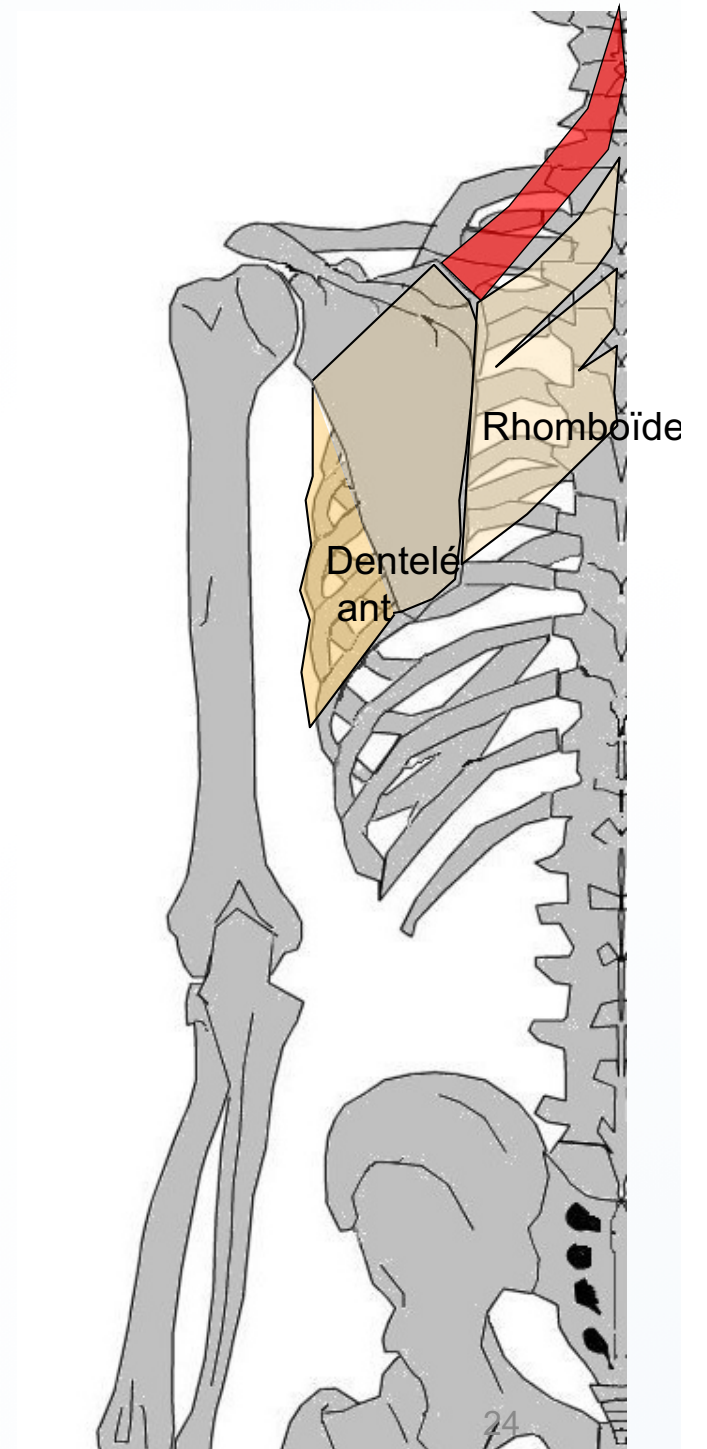
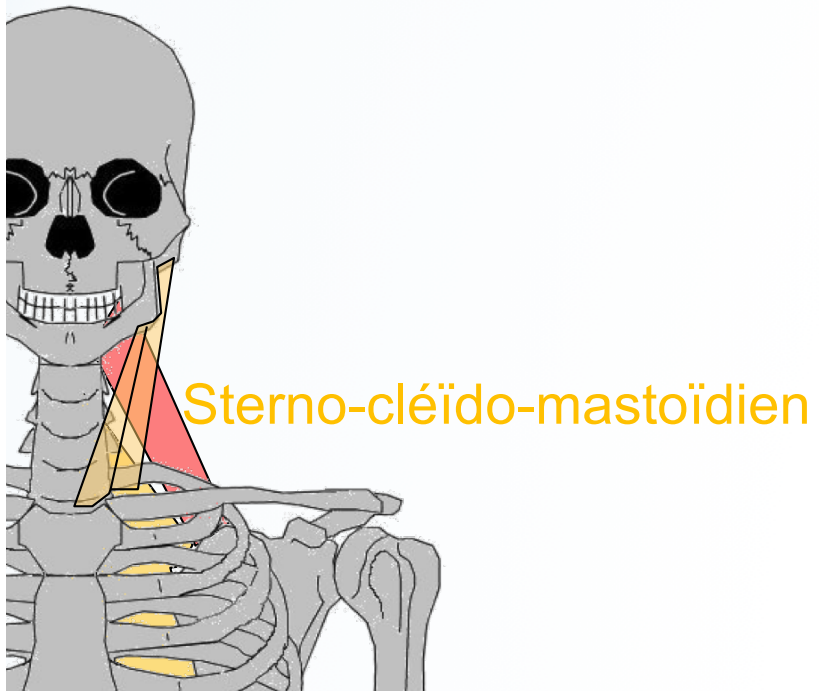
Grand rond (GR)



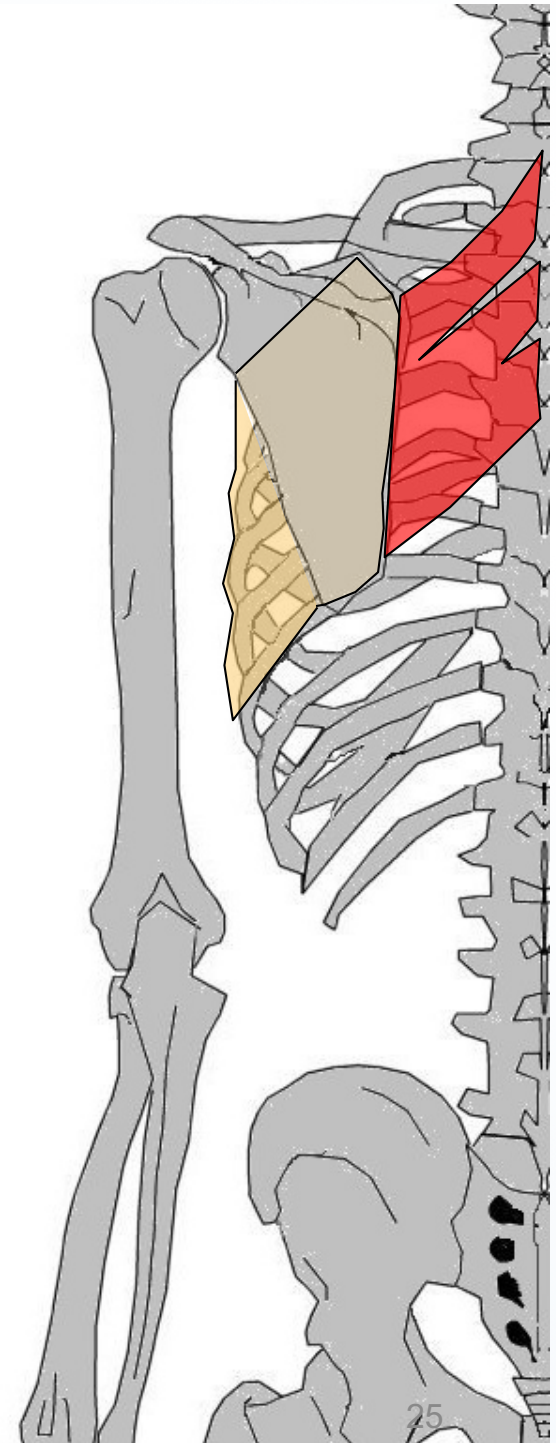


Muscles du Tronc et Muscles moteurs de l'Épaule

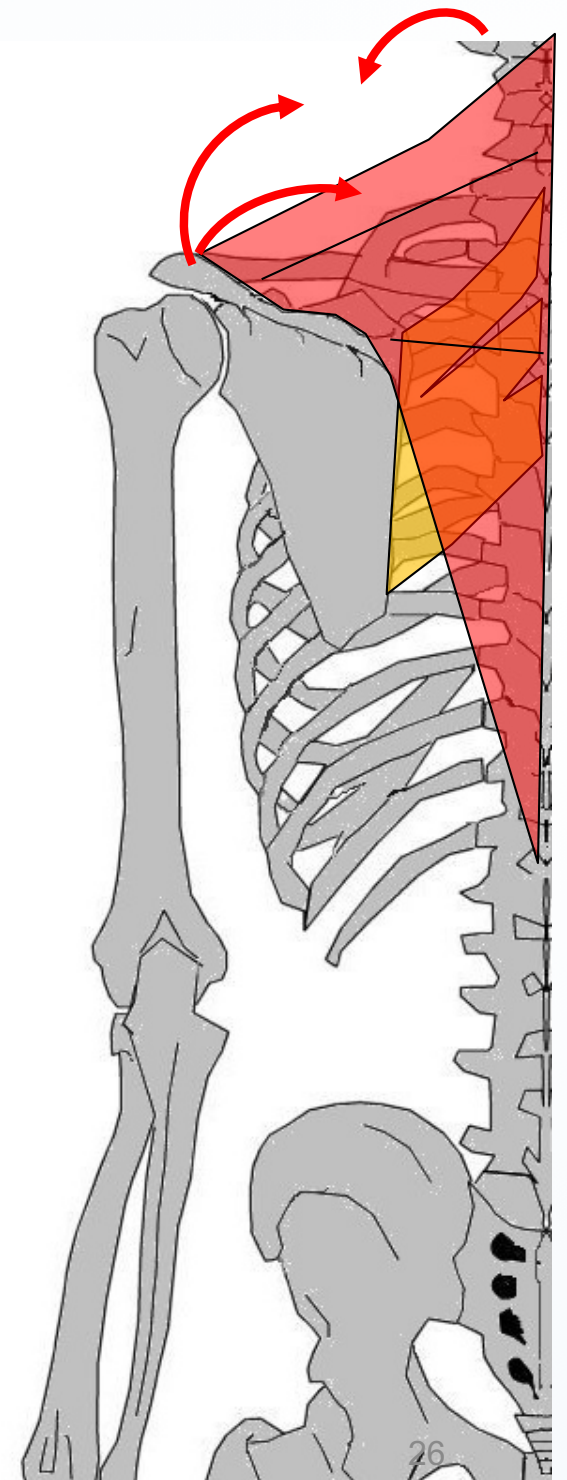
Élévateur de la scapula



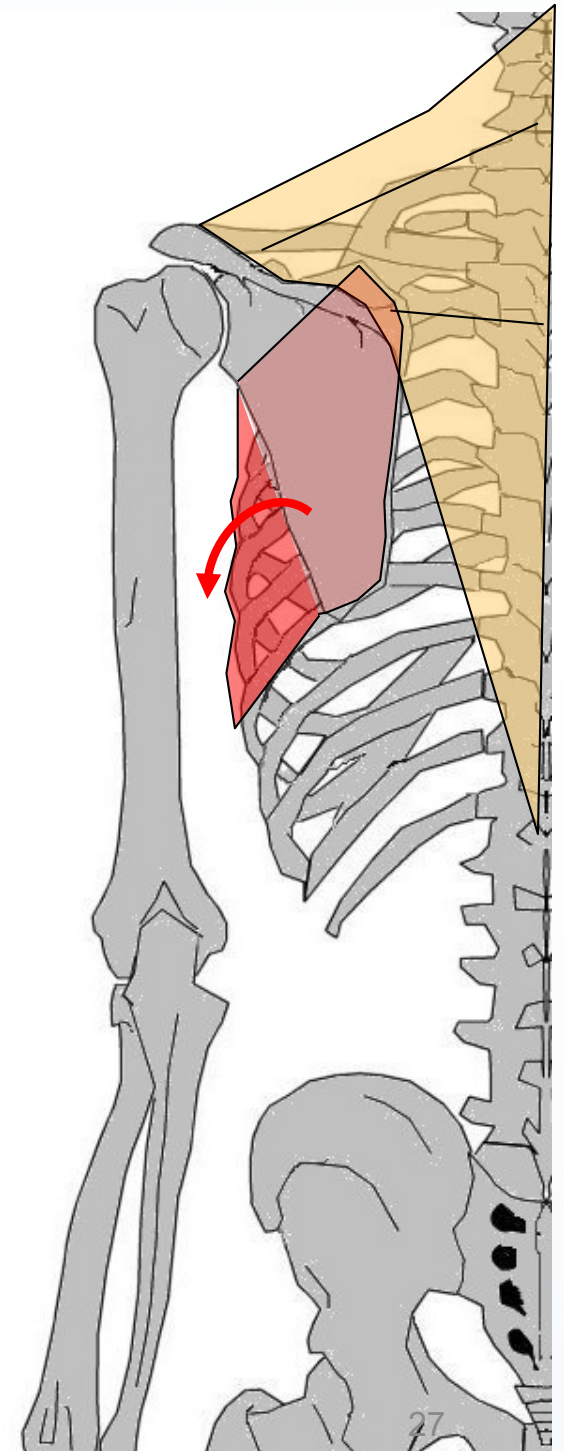
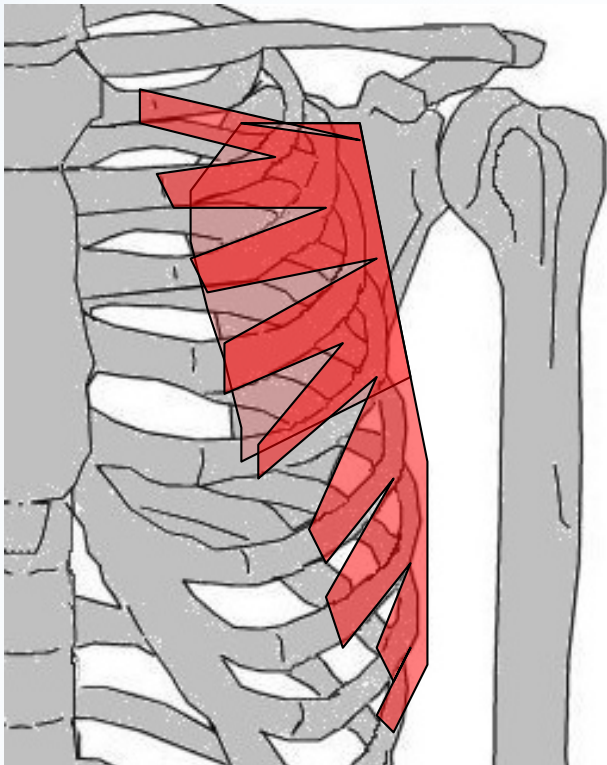
Rhomboide



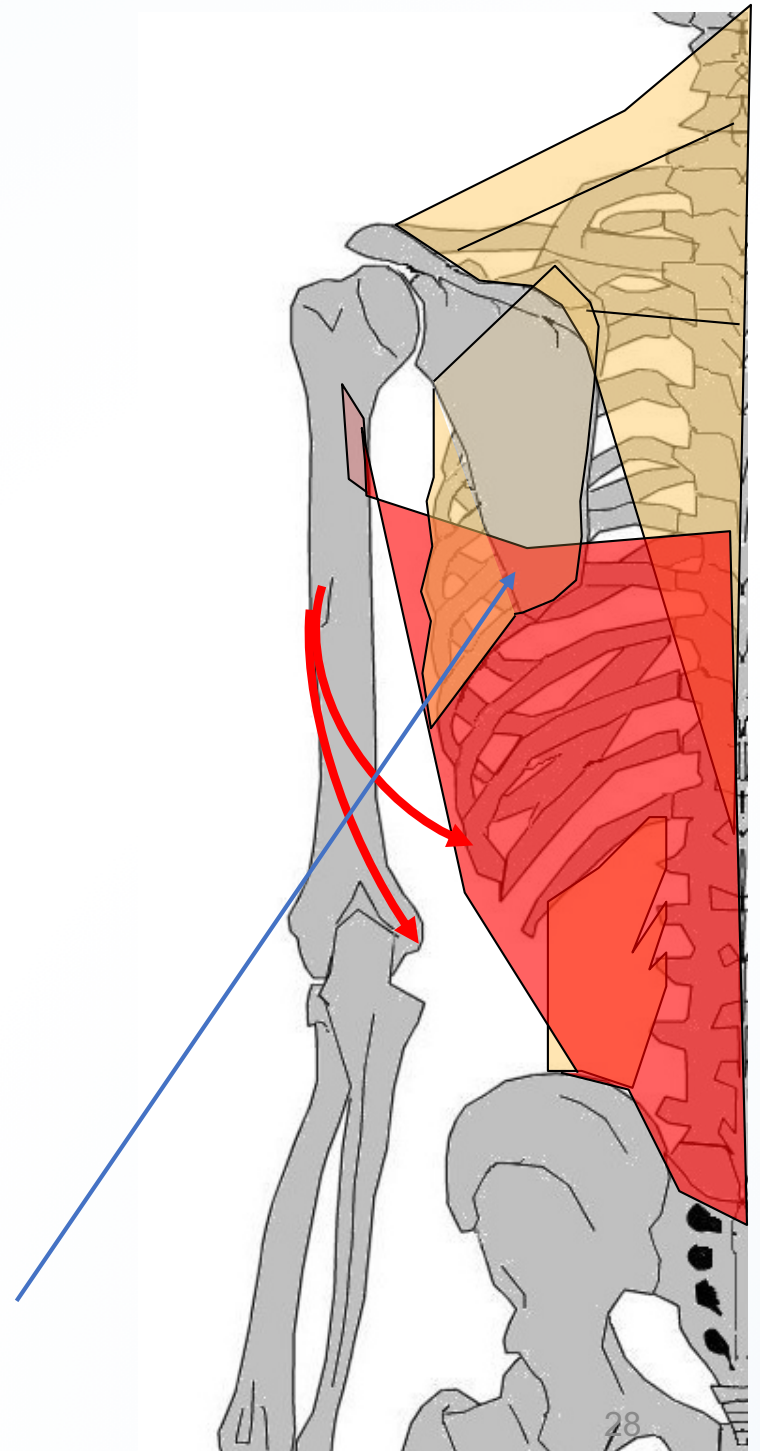
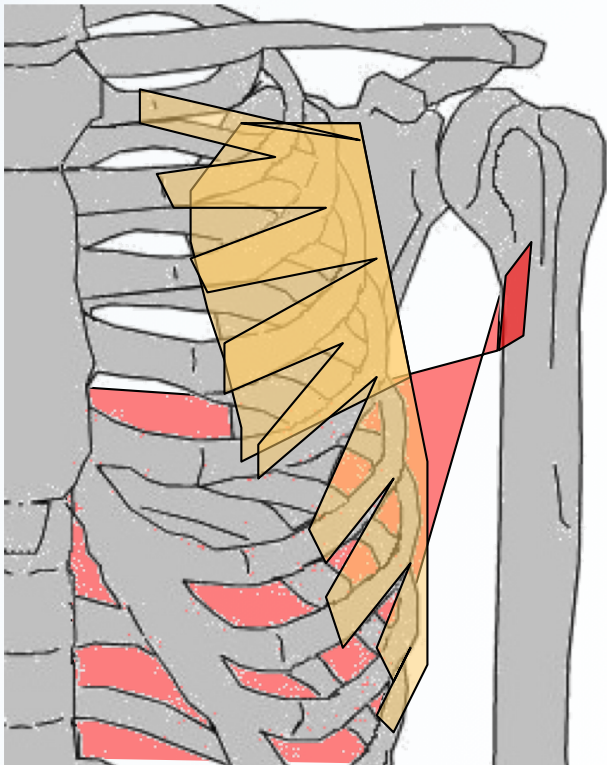
Trapèze



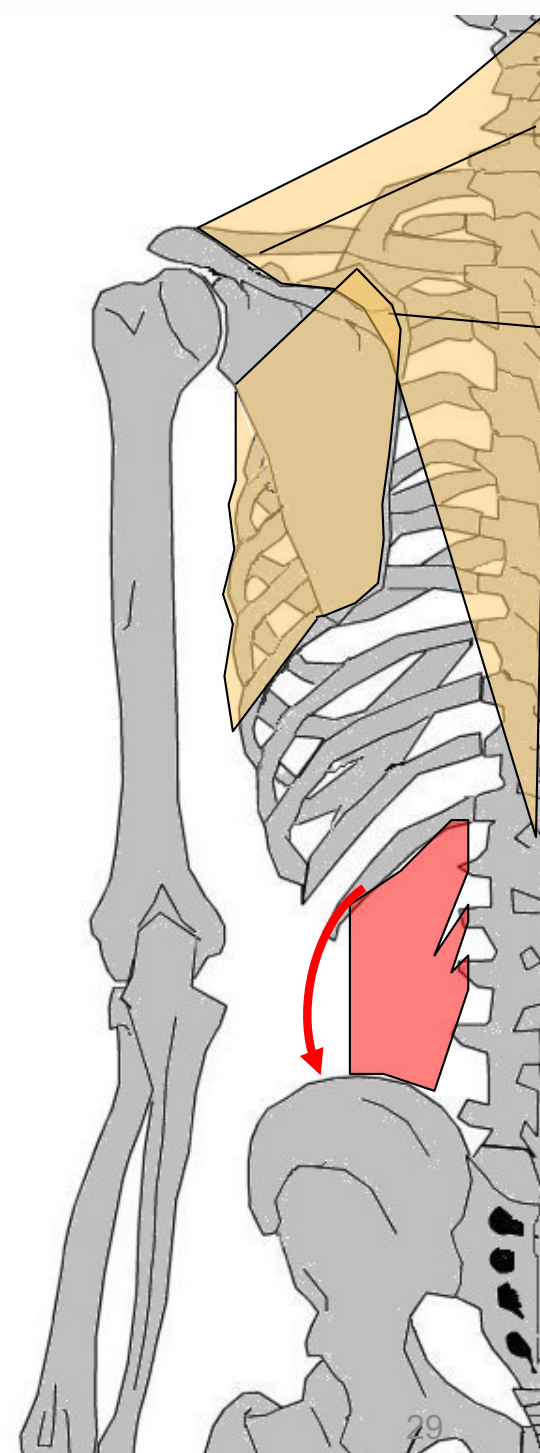
Dentelé ant (ex *g^d* dentelé)



Grand dorsal



Carré des lombes



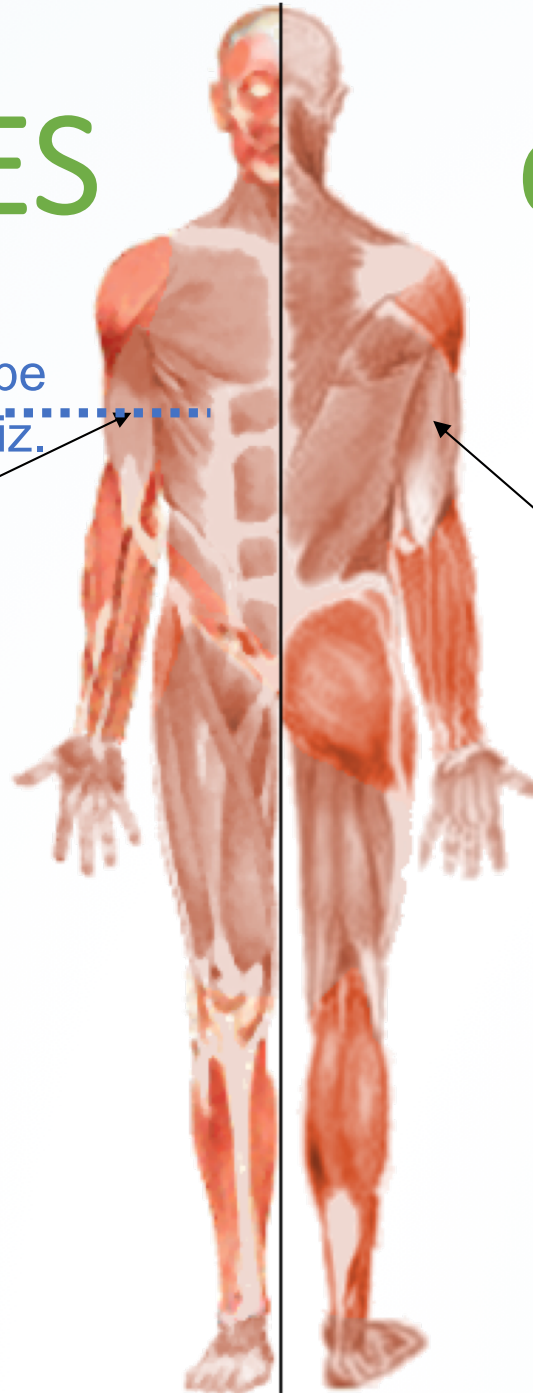
Les 2 LOGES

du BRAS

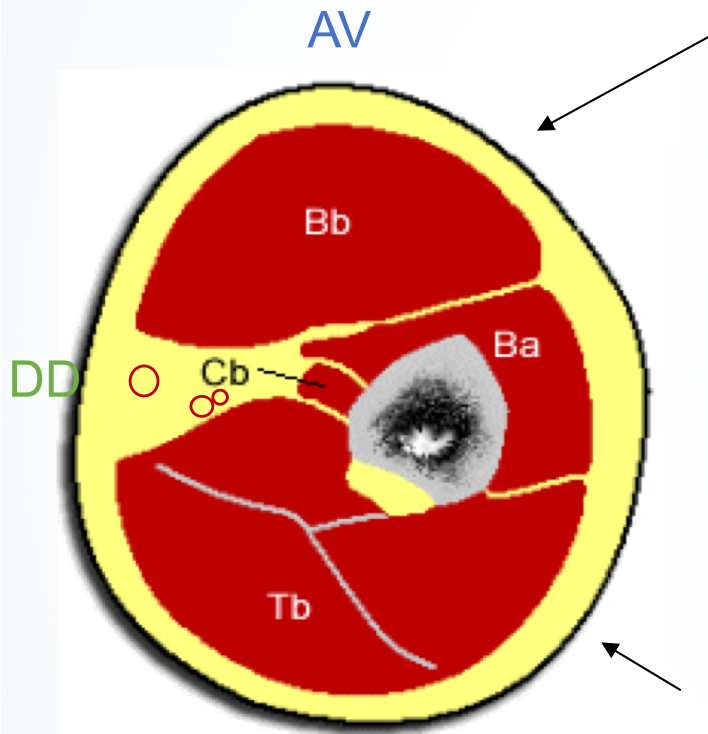
Coupe
Horiz.

Loge antérieure
(Fléchisseurs)

Loge postérieure
(Extenseurs)



COUPE DU BRAS DR



Vue >

Loge antérieure (FLÉCHISSEURS)

- **plan profond**

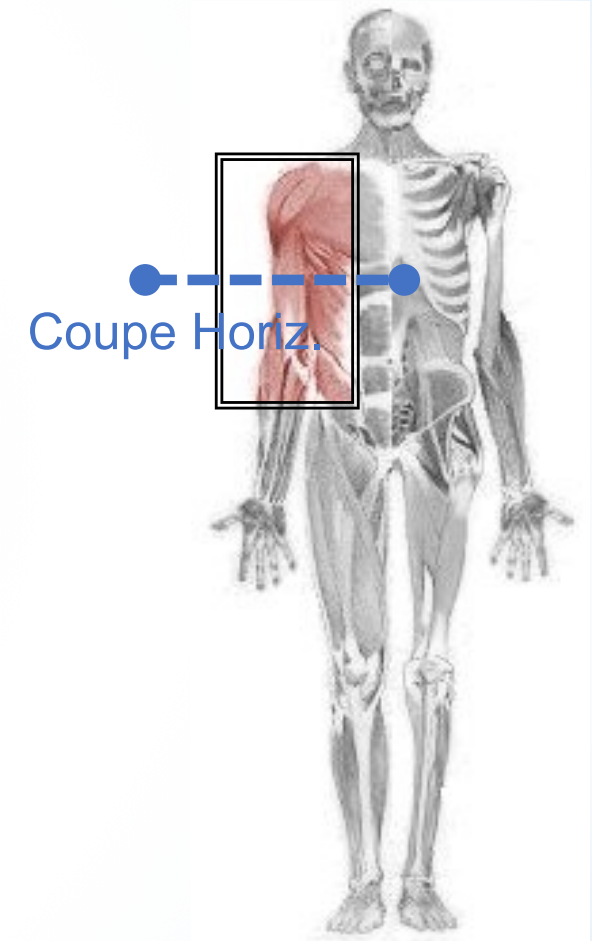
Coraco-brachial (Cb, Cf. M. épaule), Brachial (Ba)

- **plan superficiel**

Biceps brachial (Bb)

Loge postérieure (EXTENSEURS)

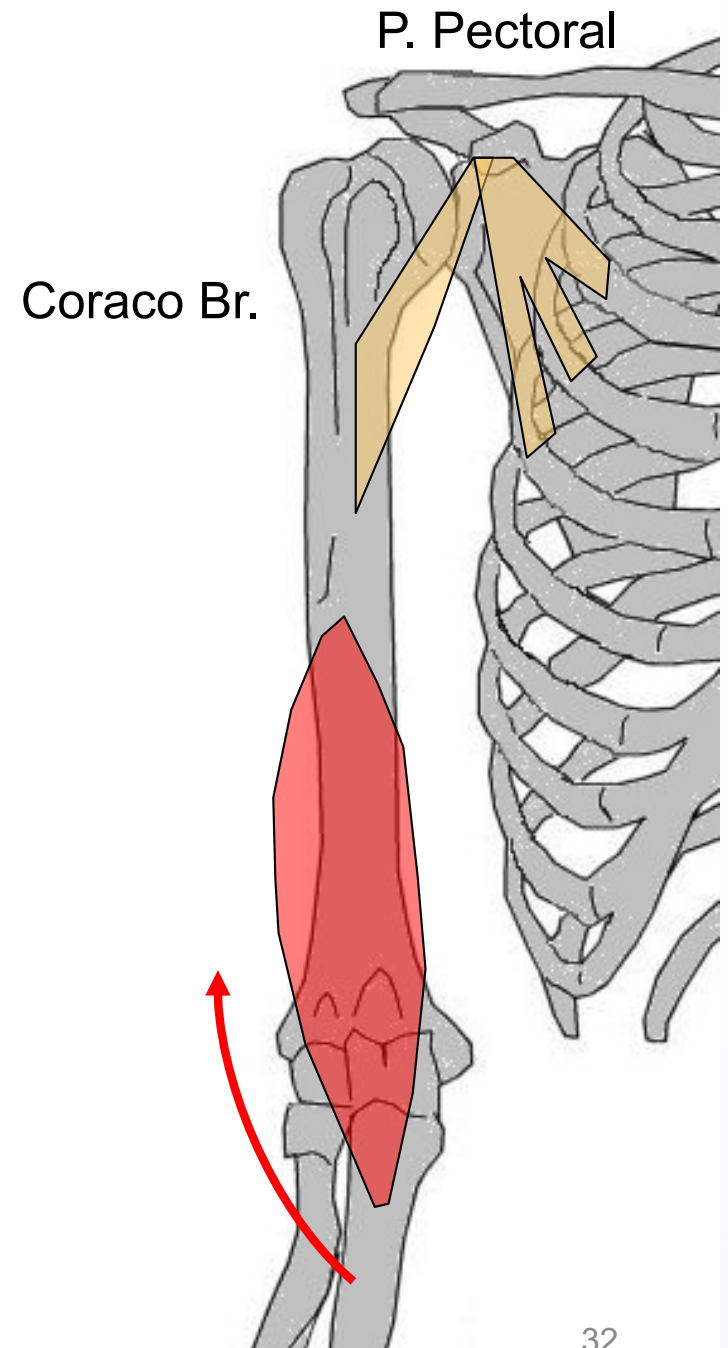
Triceps brachial (Tb)



NB: certains muscles ne sont pas visibles au niveau de cette coupe

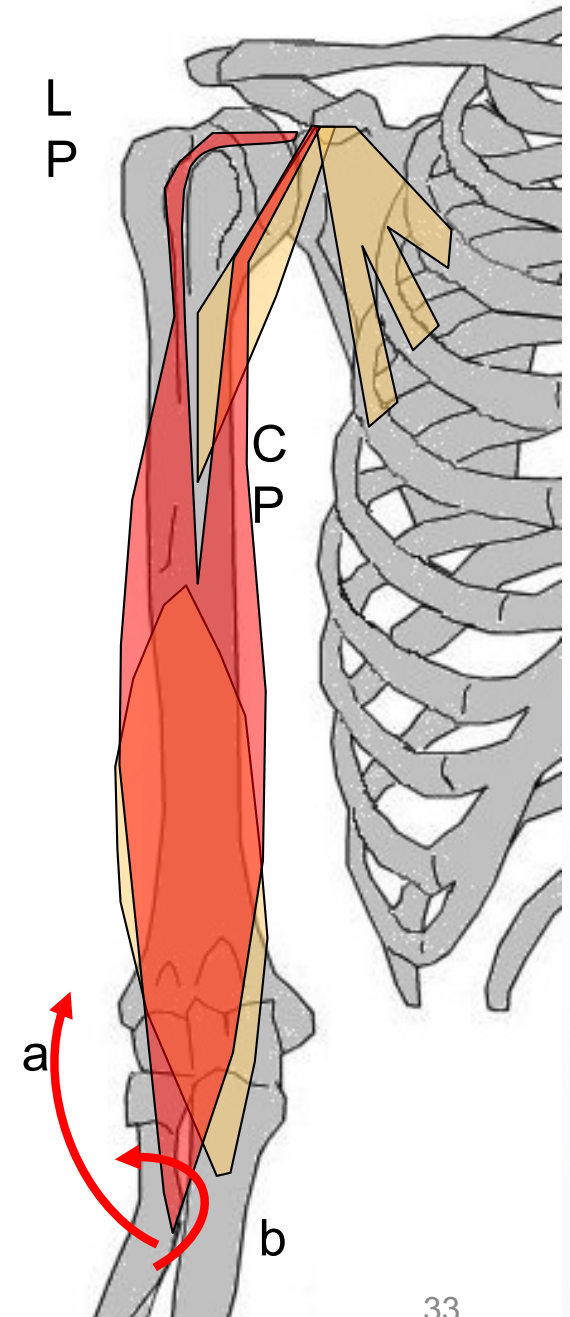
LOGE ANTÉRIEURE DU BRAS

Brachial
(ex. brachial ant)



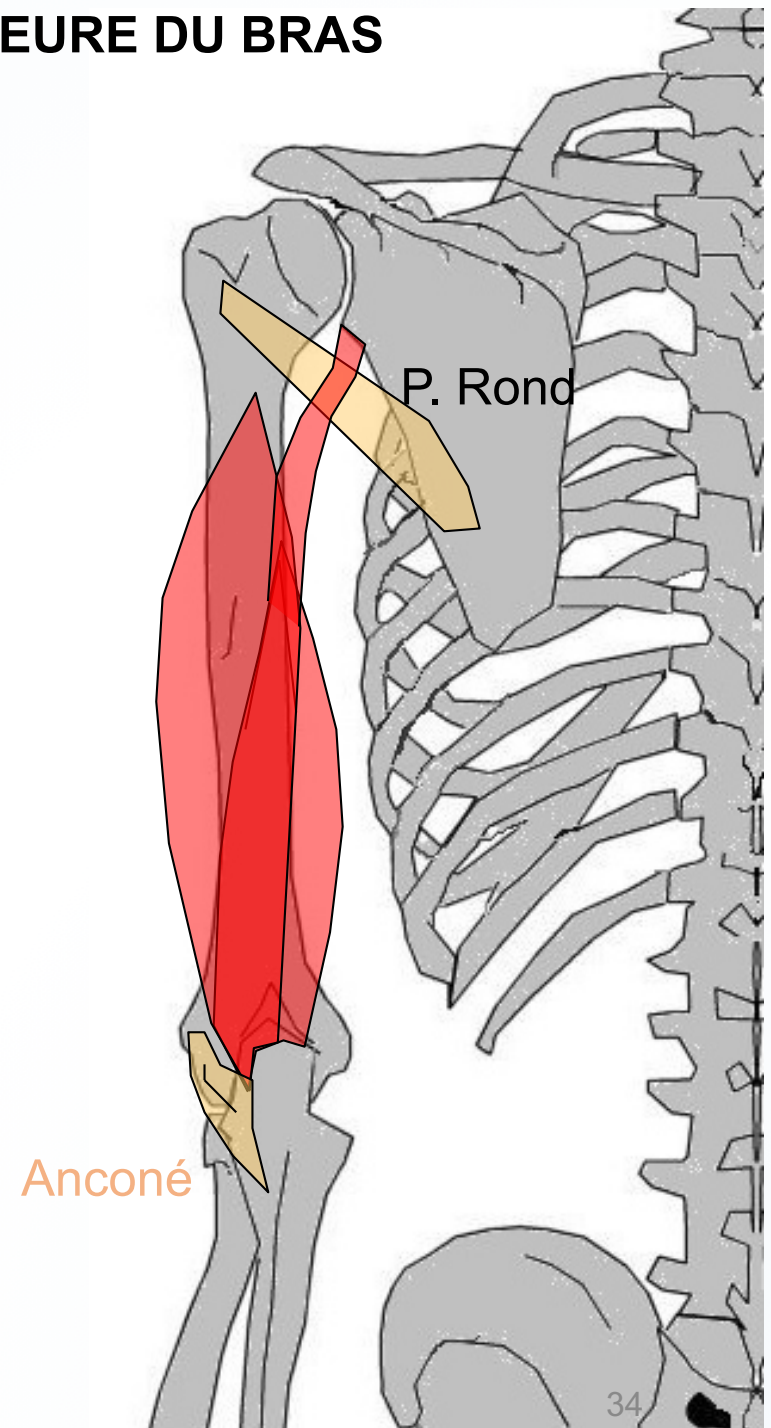
LOGE ANTÉRIEURE DU BRAS

Biceps brachial



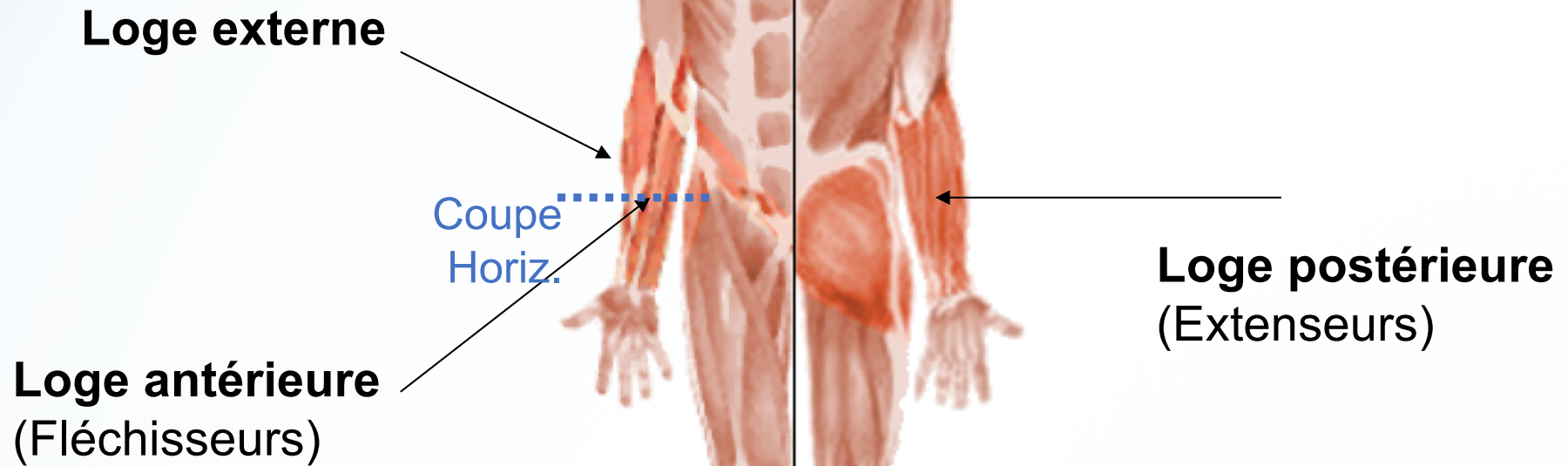
LOGE POSTÉRIEURE DU BRAS

Triceps brachial



Les 3 LOGES

de l'AV-BRAS



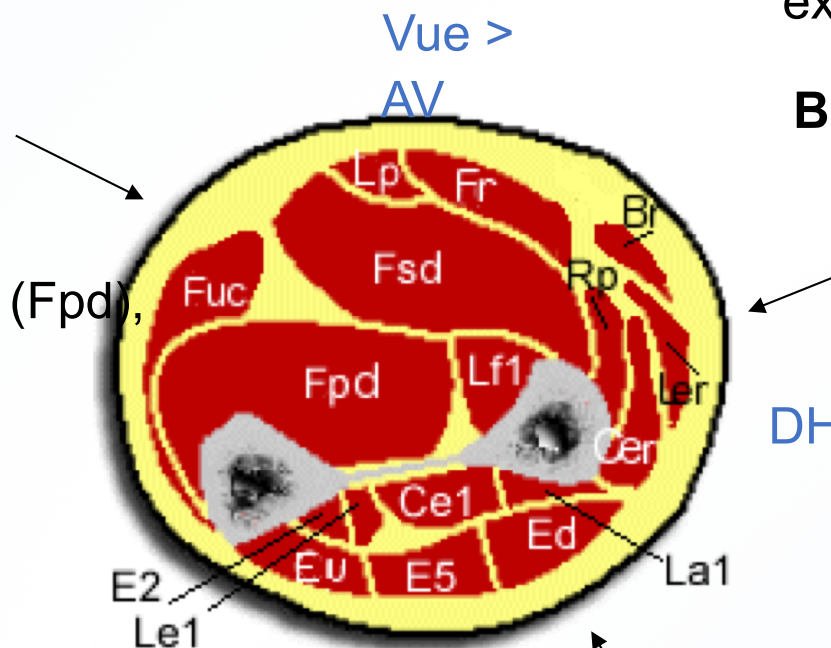
COUPE DE L'AVANT-BRAS DR

Loge antérieure (FLÉCHISSEURS)

- **plan superficiel** : Rond pronateur , Fléchis. radial du carpe (Fr), Lg Palmaire (Lp), Fléch. ulnaire du carpe (Fuc)
- **plan moyen** : Fléchis. superficiel des doigts (Fsd)
- **plan profond** : Carré pronateur (*non visible*), Fléchisseur profond des doigts (Fpd), Lg fléchisseur du I (Lf1)

Loge externe

Lg extenseur radial du carpe (Ler), Court extenseur radial du carpe (Cer), **Brachio-radial** (Br)



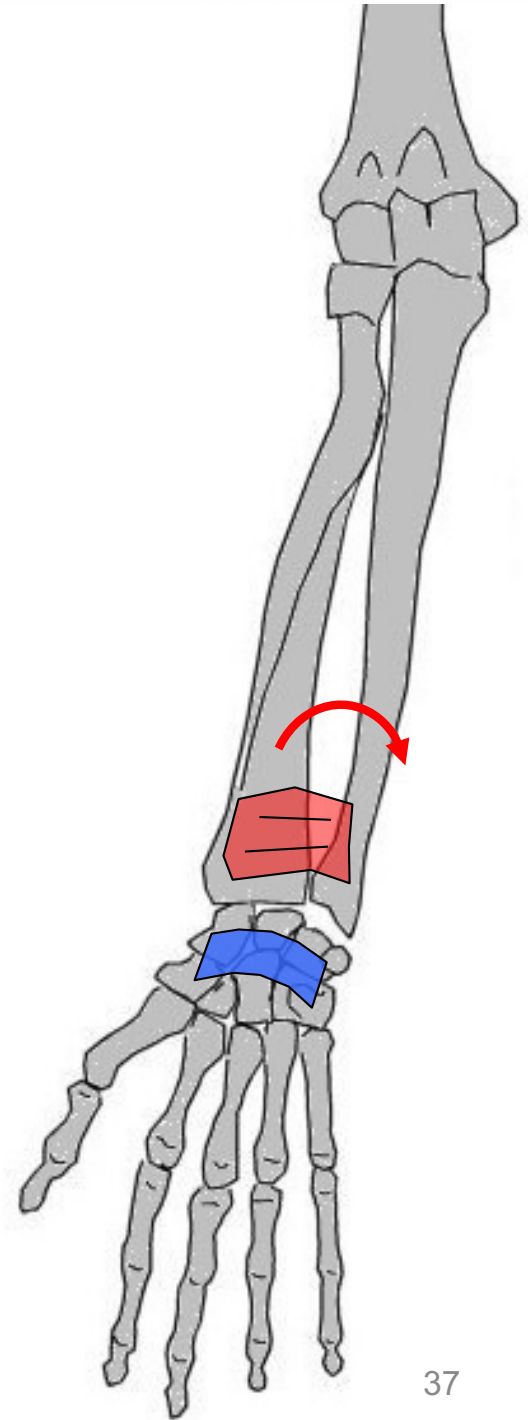
NB: certains muscles ne sont pas visibles au niveau de cette coupe

Loge postérieure (EXTENSEURS)

- **plan superficiel** : Ext. des doigts (Ed), Ext. du V (E5), Ext. ulnaire du carpe (Eu), Anconé (*non visible*)
- **plan profond** : Lg Abducteur du I (La1), Court ext. du I (Ce1), Lg ext. du I (Le1), Ext. propre du II (E2), Supinateur (*non visible*)

LOGE ANTÉRIEURE PLAN PROFOND de l'AV-BRAS

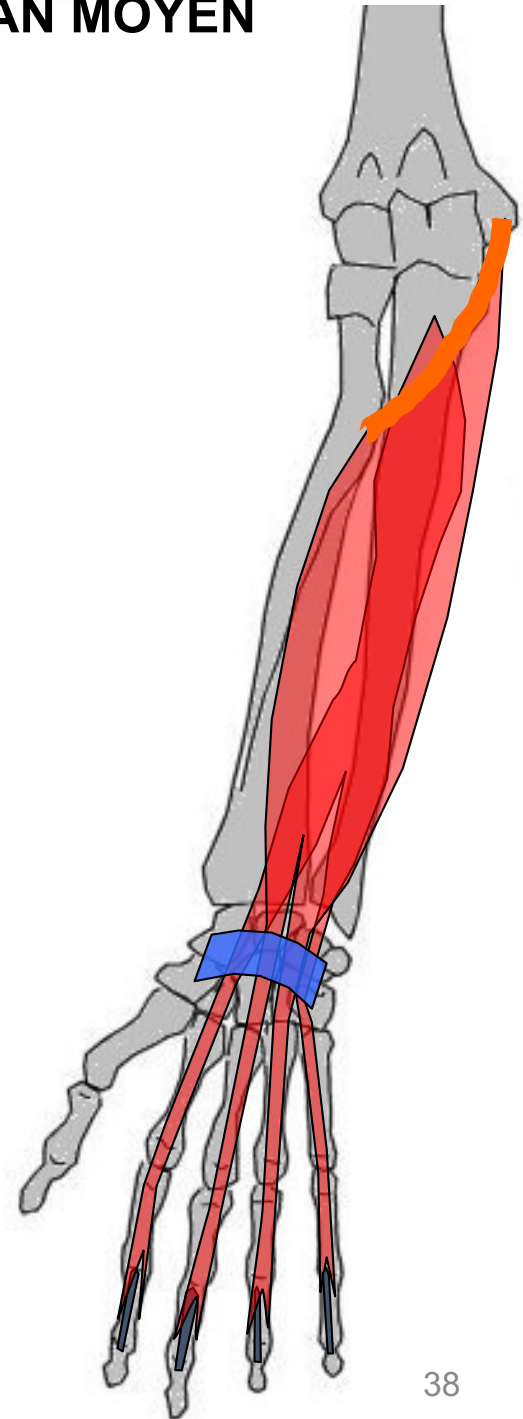
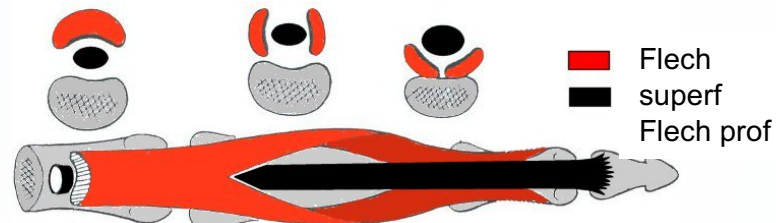
Carré pronateur



LOGE ANTÉRIÈRE PLAN MOYEN

Fléchisseur superficiel des doigts

Vue palmaire

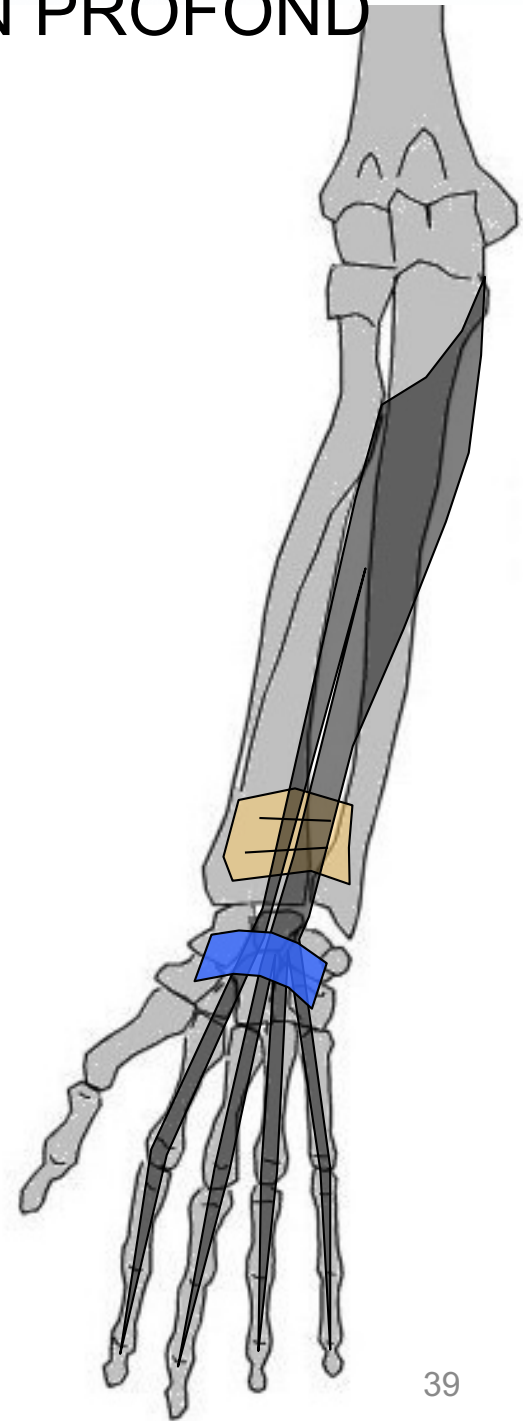



se divise en 2 languettes au niveau de l'X^e métacarpo-phalangienne pour laisser passer Flech prof

LOGE ANTÉRIÈRE PLAN PROFOND

Fléchisseur profond des doigts

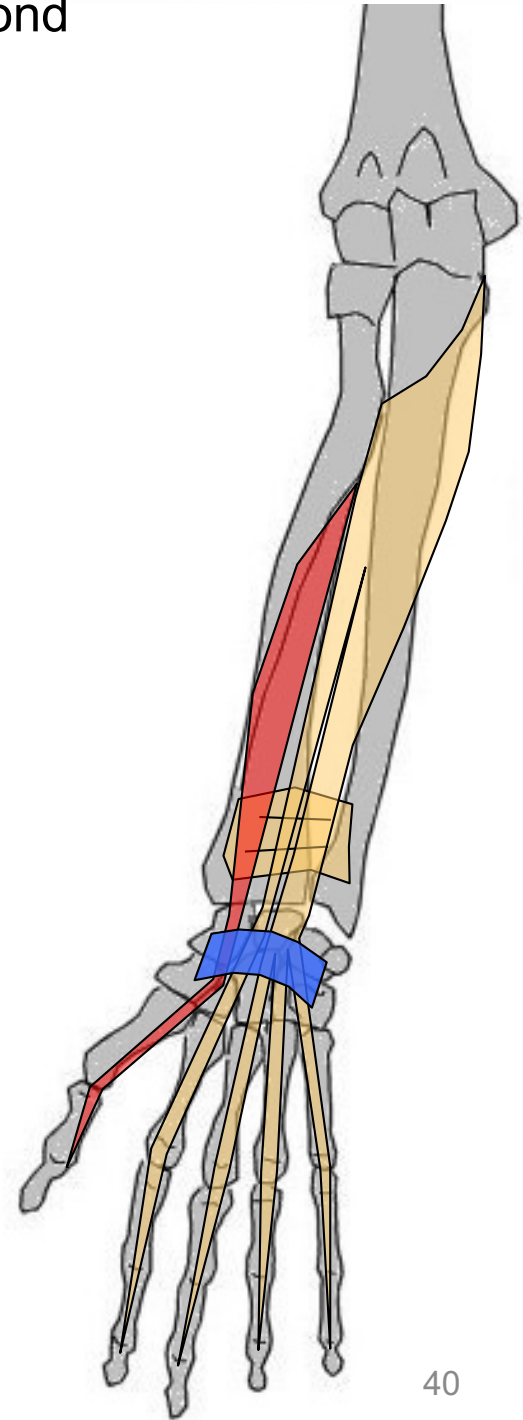
Vue palmaire



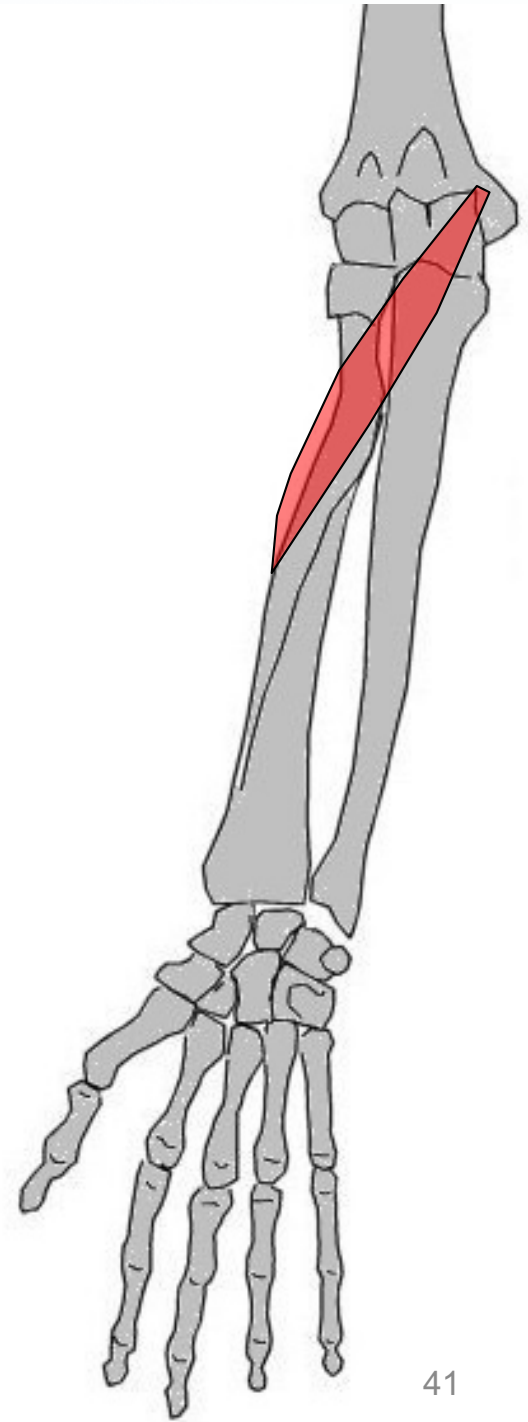
FLECH prof traverse le Fflech superficiel des doigts

Loge antérieure plan profond

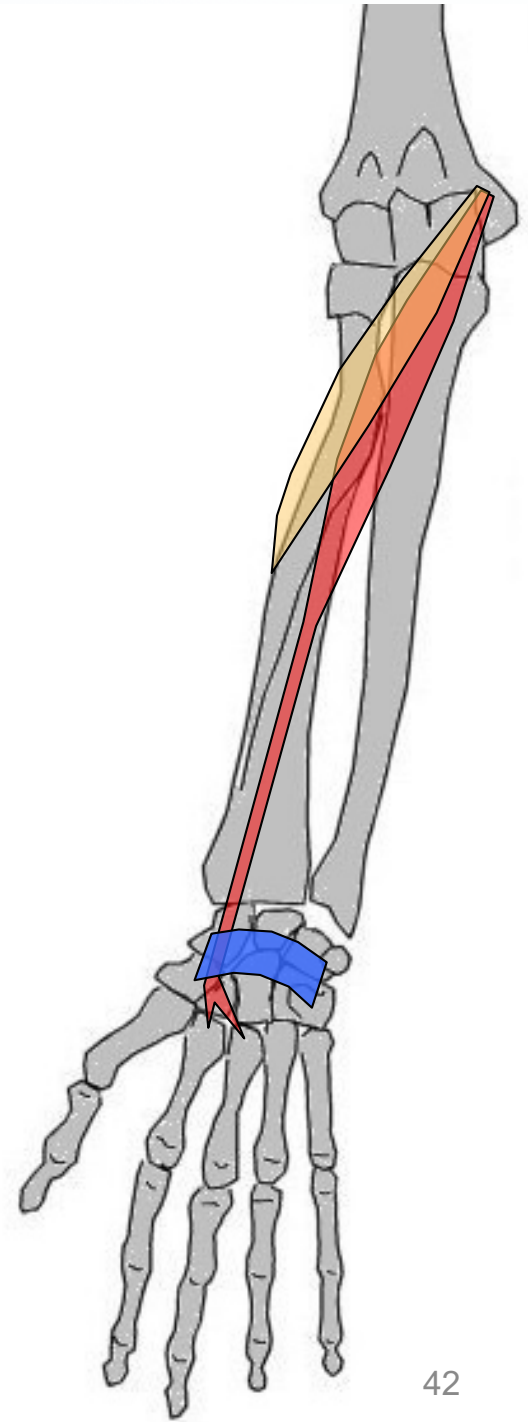
Long fléchisseur du I



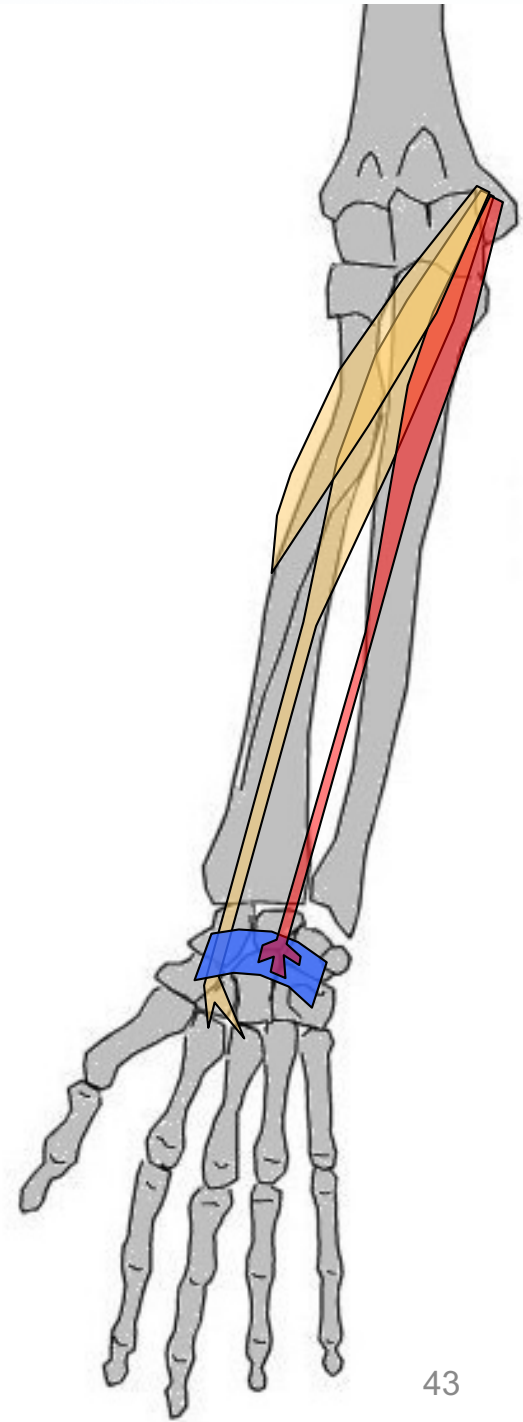
Rond pronateur



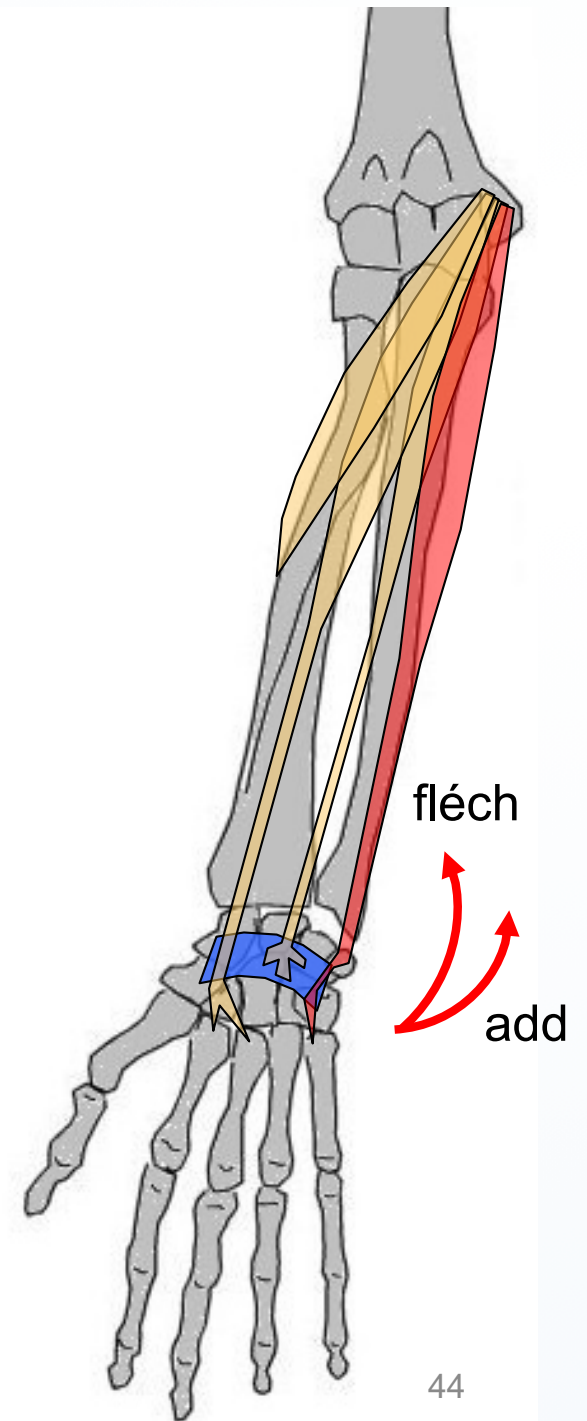
Grand palmaire



Petit palmaire

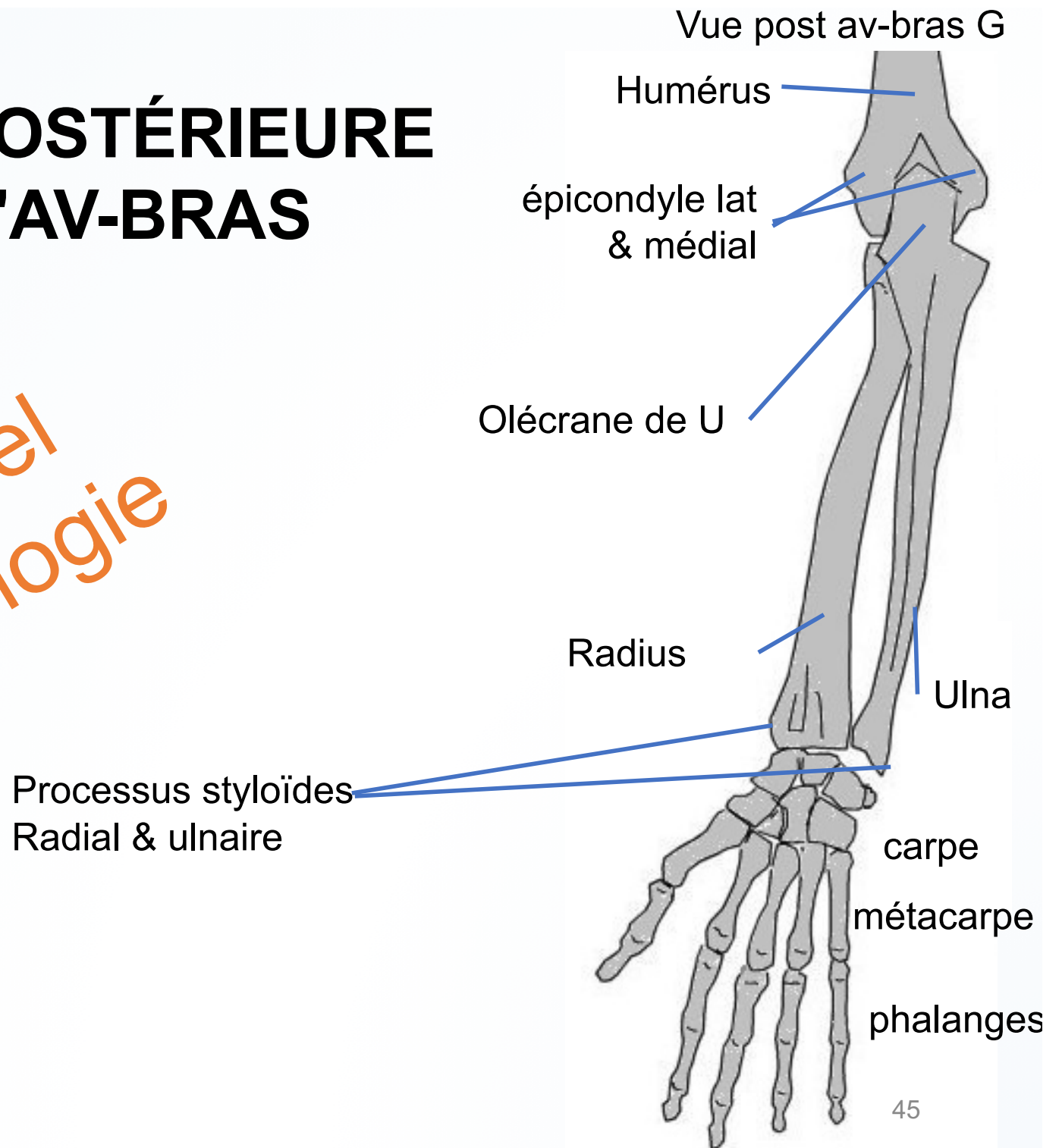


Fléchisseur ulnaire du carpe (*ex. cubital ant.*)



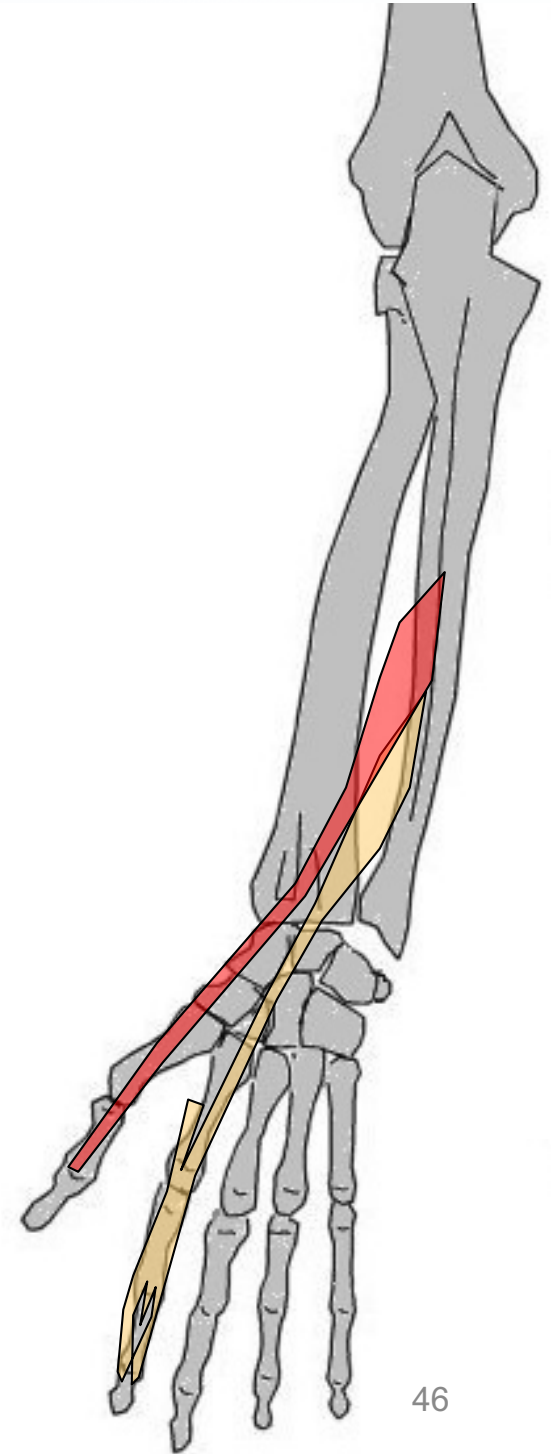
LOGE POSTÉRIEURE de l'AV-BRAS

Rappel
ostéologie

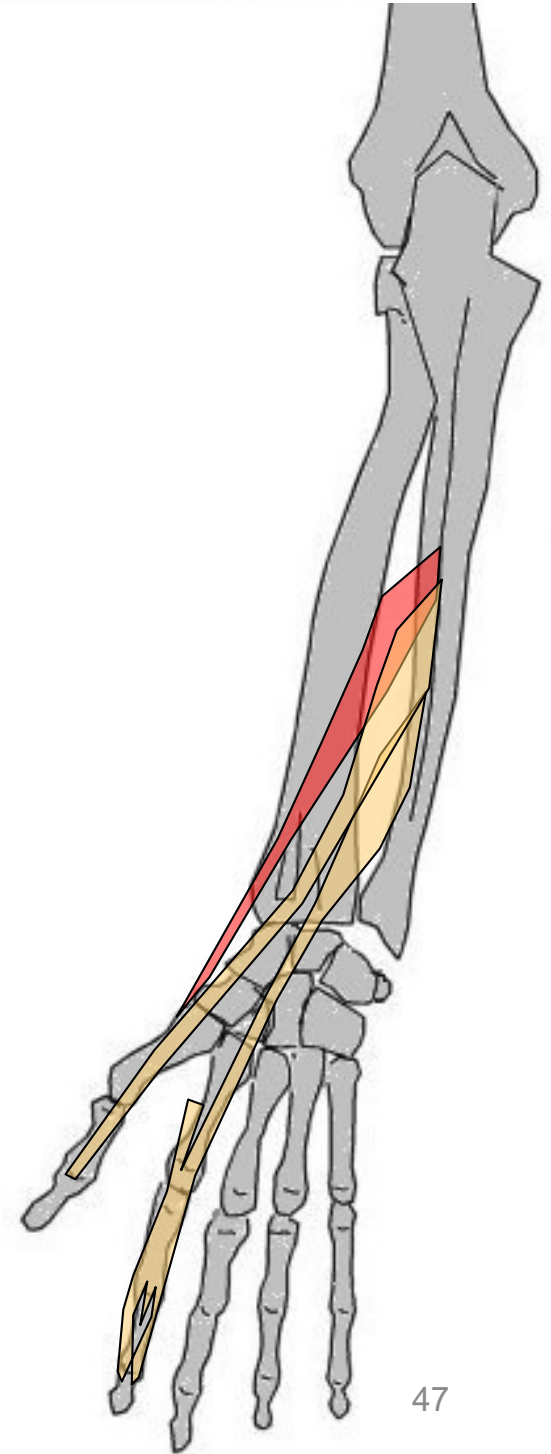


Long extenseur du I

Extenseur (propre) du II

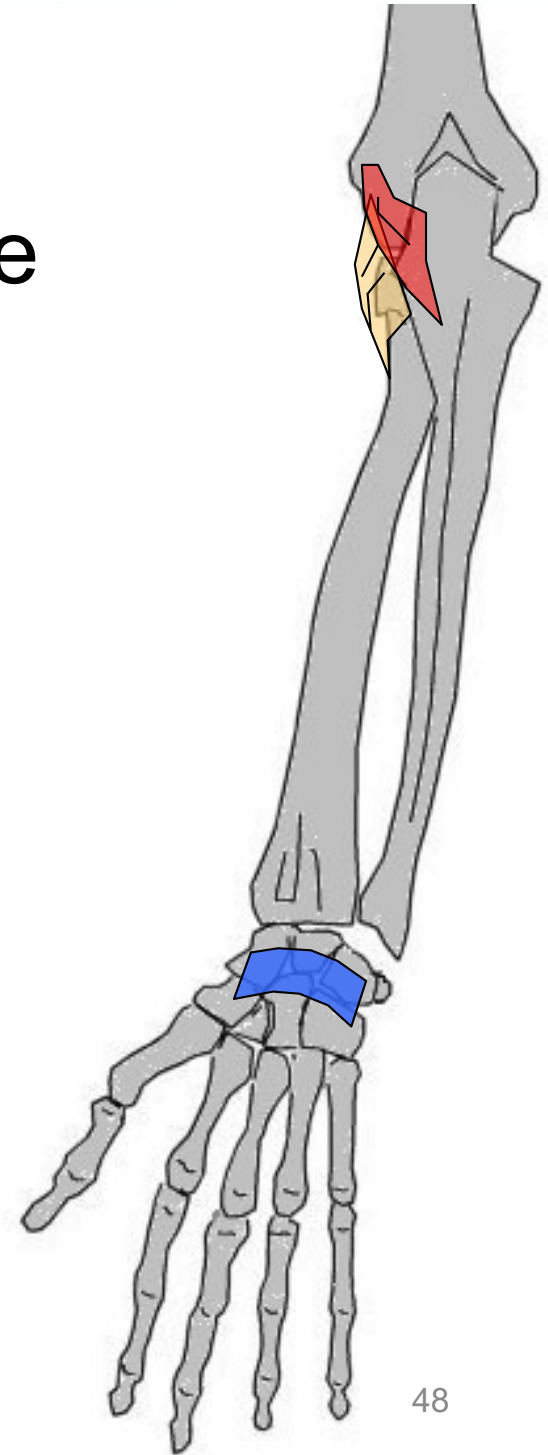


Long abducteur du I



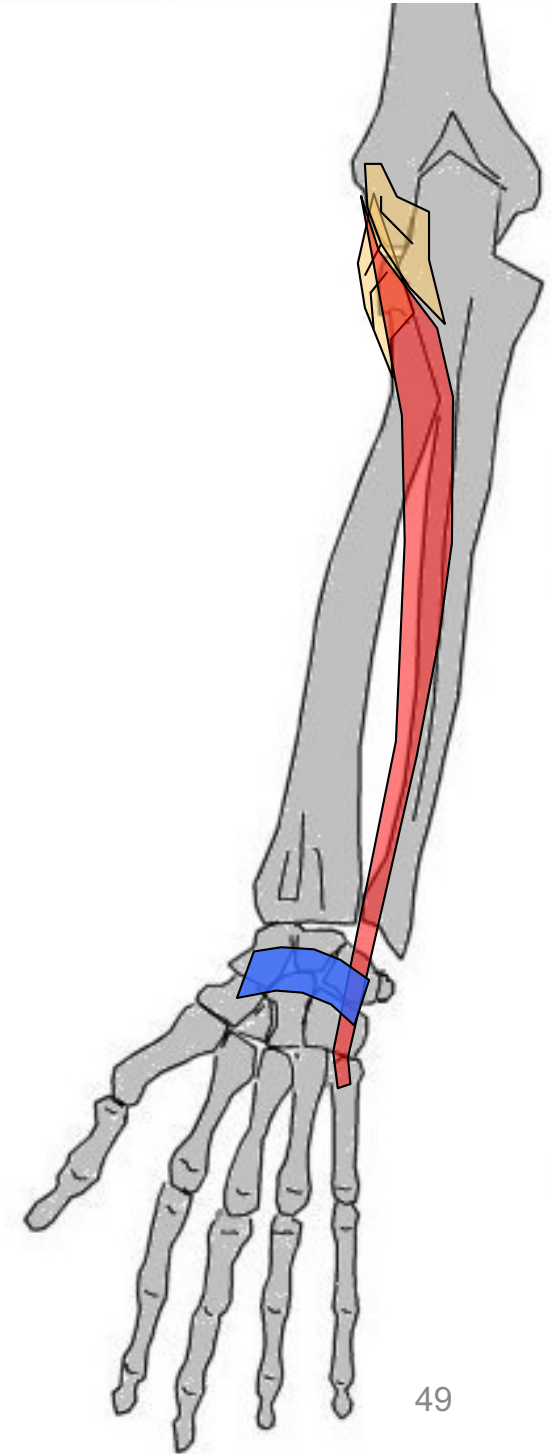
Anconé

Loge POST plan superficielle



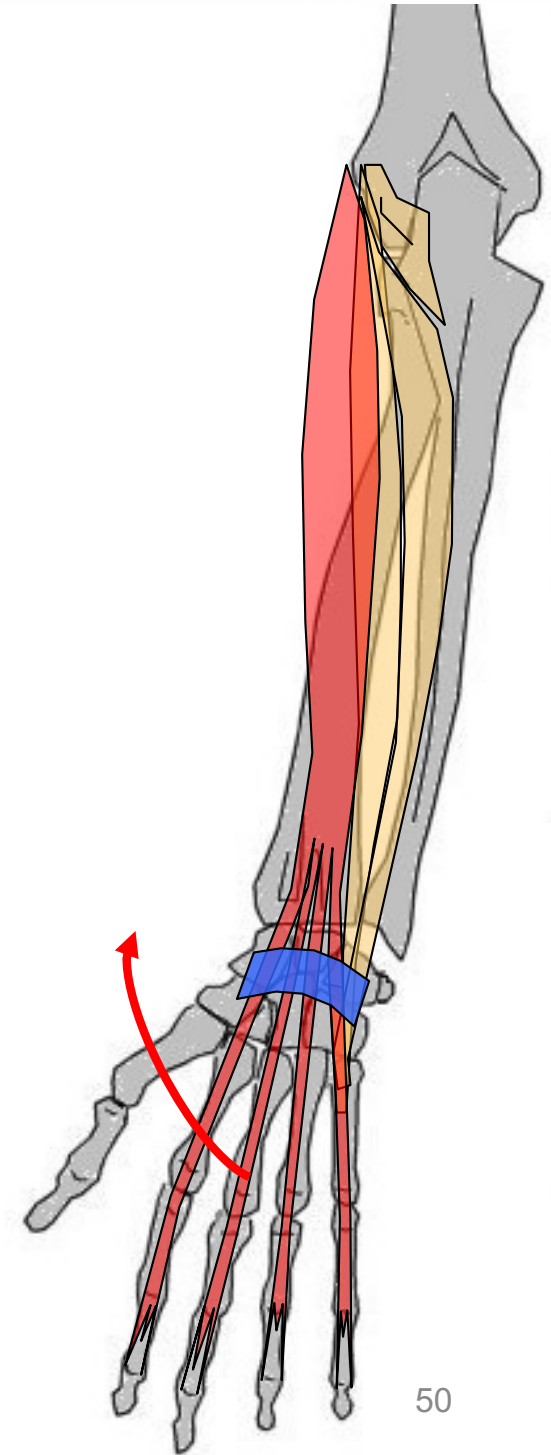
Cubital postérieur

Loge post plan superficielle

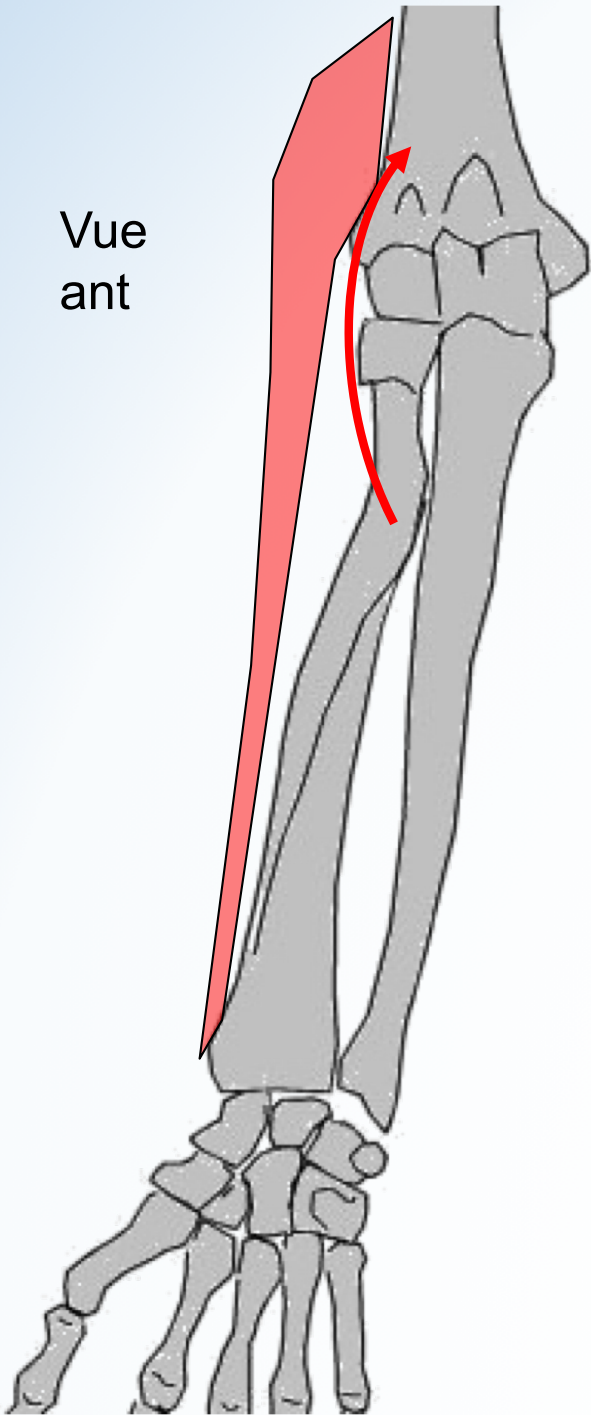


Extenseur des doigts

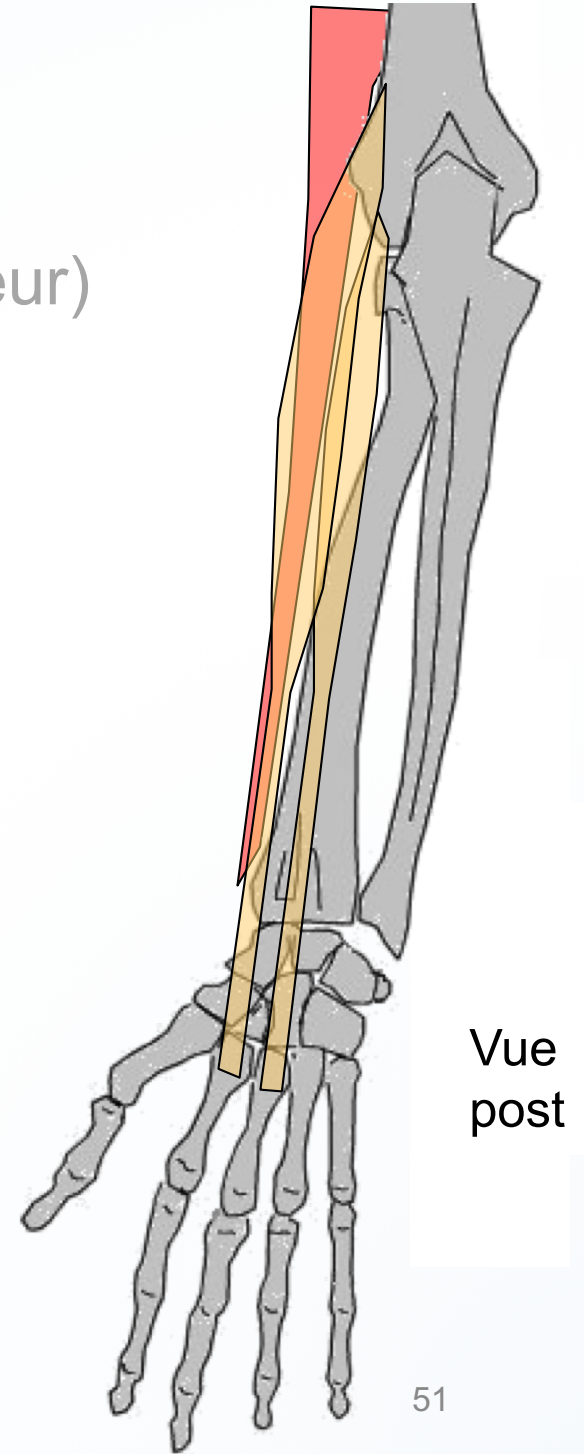
(ex. Ext commun des doigts)
Loge post plan superficielle



Vue
ant



Brachio radial
(ex. HSR, ex lg supinateur)



Vue
post

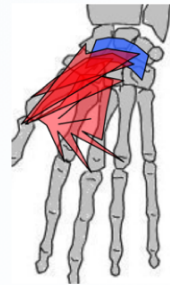
MUSCLES DE LA MAIN

3 groupes

- **muscles de l'éminence thénar** (dédié au I)
- **muscles de l'éminence hypothénar** (→V)
 - **moyen** (entre les métacarpiens)

MUSCLES DE LA MAIN

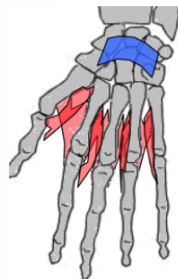
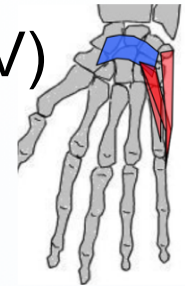
Groupe des muscles de l'**éminence thénar** (→ pouce)



- Adducteur du I
- Court abducteur du I
- Court fléchisseur du I
- Opposant du I

Groupe des Muscles de l'**éminence hypothénar** (→ V)

- Opposant du V
- Court fléchisseur du V
- Adducteur du V
- Court palmaire



Groupe moyen (entre métacarpiens)

- Interosseux dorsaux
- Interosseux palmaires